


# Accepted Manuscript



Blau Syndrome - Associated Uveitis: Preliminary Results from an International Prospective Interventional Case Series.

Inge L. Sarens, Ingele Casteels, Jordi Anton, Brigitte Bader-Meunier, Philippe Brissaud, Gaelle Chédeville, Rolando Cimaz, Andrew D. Dick, Graciella Espada, Jorge Fernandez-Martin, Catherine M. Guly, Eric Hachulla, Miroslav Harjacek, Raju Khubchandani, Friederike Mackensen, Rosa Merino, Consuelo Modesto, Antonio Naranjo, Sheila Oliveira-Knupp, Seza Özen, Christine Pajot, Athimalaipet V. Ramanan, Ricardo Russo, Gordana Susic, Akaluck Thatayatikom, Caroline Thomée, Sebastiaan Vastert, John Bertin, Juan I. Arostegui, Carlos D. Rose, Carine H. Wouters

PII: S0002-9394(17)30371-9

DOI: [10.1016/j.ajo.2017.08.017](https://doi.org/10.1016/j.ajo.2017.08.017)

Reference: AJOPHT 10242

To appear in: *American Journal of Ophthalmology*

Received Date: 1 May 2016

Revised Date: 25 August 2017

Accepted Date: 26 August 2017

Please cite this article as: Sarens IL, Casteels I, Anton J, Bader-Meunier B, Brissaud P, Chédeville G, Cimaz R, Dick AD, Espada G, Fernandez-Martin J, Guly CM, Hachulla E, Harjacek M, Khubchandani R, Mackensen F, Merino R, Modesto C, Naranjo A, Oliveira-Knupp S, Özen S, Pajot C, Ramanan AV, Russo R, Susic G, Thatayatikom A, Thomée C, Vastert S, Bertin J, Arostegui JI, Rose CD, Wouters CH, Blau Syndrome - Associated Uveitis: Preliminary Results from an International Prospective Interventional Case Series., *American Journal of Ophthalmology* (2017), doi: 10.1016/j.ajo.2017.08.017.

This is a PDF file of an unedited manuscript that has been accepted for publication. As a service to our customers we are providing this early version of the manuscript. The manuscript will undergo copyediting, typesetting, and review of the resulting proof before it is published in its final form. Please note that during the production process errors may be discovered which could affect the content, and all legal disclaimers that apply to the journal pertain.

**Abstract**

*Purpose:* Provide baseline and preliminary follow-up results in a 5-year longitudinal study of Blau syndrome

*Design:* Multicenter, prospective interventional case series

*Methods:* Baseline data from 50 patients from 25 centers worldwide, and follow-up data for patients followed 1, 2 or 3 years at the end of study enrolment. Ophthalmic data were collected at baseline and yearly visits by means of a standardized collection form.

*Results:* Median age at onset of eye disease was 60 months and duration of eye disease at baseline 145 months. At baseline 38 patients (78%) had uveitis, bilateral in 37 (97%). Eight patients (21%) had moderate to severe visual impairment. Panuveitis was found in 38 eyes (51%), with characteristic multifocal choroidal infiltrates in 29 eyes (39%). Optic disc pallor in 9 eyes (12%) and peripapillary nodules in 9 eyes (12%) were the commonest signs of optic nerve involvement. Active anterior chamber inflammation was noted in 30 eyes (40%) at baseline and in 16 (34%), 17 (57%) and 11 (61%) of eyes at 1, 2 and 3 year respectively. Panuveitis was associated with longer disease duration. At baseline, 56 eyes (75%) were on topical corticosteroids. Twenty-six patients (68%) received a combination of systemic corticosteroids and immunomodulatory therapy.

*Conclusions:* Blau uveitis is characterized by progressive panuveitis with multifocal choroiditis, resulting in severe ocular morbidity in spite of continuous systemic and local immunomodulatory therapy. The frequency and severity of Blau uveitis highlight the need for close ophthalmologic surveillance as well as a search for more effective therapies.

# Blau Syndrome - Associated Uveitis: Preliminary Results from an International Prospective Interventional Case Series.

Inge L. Sarens<sup>1</sup>, Ingele Casteels<sup>1</sup>, Jordi Anton<sup>2</sup>, Brigitte Bader-Meunier<sup>3</sup>, Philippe Brissaud<sup>4</sup>, Gaëlle Chédeville<sup>5</sup>, Rolando Cimaz<sup>6</sup>, Andrew D. Dick<sup>7</sup>, Graciella Espada<sup>8</sup>, Jorge Fernandez-Martin<sup>9</sup>, Catherine M. Guly<sup>7</sup>, Eric Hachulla<sup>10</sup>, Miroslav Harjacek<sup>11</sup>, Raju Khubchandani<sup>12</sup>, Friederike Mackensen<sup>13\*</sup>, Rosa Merino<sup>14</sup>, Consuelo Modesto<sup>15</sup>, Antonio Naranjo<sup>16</sup>, Sheila Oliveira-Knupp<sup>17</sup>, Seza Özen<sup>18</sup>, Christine Pajot<sup>19</sup>, Athimalaipet V. Ramanan<sup>20</sup>, Ricardo Russo<sup>21</sup>, Gordana Susic<sup>22</sup>, Akaluck Thatayatikom<sup>23</sup>, Caroline Thomée<sup>24</sup>, Sebastiaan Vastert<sup>25</sup>, John Bertin<sup>26</sup>, Juan I. Arostegui<sup>27</sup>, Carlos D. Rose<sup>28</sup> and Carine H. Wouters<sup>29</sup>

1. Department of Ophthalmology, Catholic University of Leuven (KU Leuven), Leuven, Belgium
2. Pediatric Rheumatology Unit, Hospital Sant Joan de Déu. Universitat de Barcelona, Barcelona, Spain
3. Unité d'Immunologie, Hématologie et Rhumatologie Pédiatrique, Hospital Necker-Enfants Malades, Inserm U 768, Imagine Foundation, Paris, France
4. Rheumatology Practice, Neuilly-sur-Seine, France
5. Montreal Children's Hospital, McGill University Health Center, Montreal, Quebec, Canada
6. Dipartimento de Pediatria, Università degli Studi di Firenze, Firenze, Italy
7. Bristol Eye Hospital, University Hospitals Bristol NHS Foundation Trust, Bristol, UK
8. Pediatric Rheumatology Unit, Hospital de Niños Ricardo Gutiérrez, Universidad de Buenos Aires, Buenos Aires, Argentina
9. Servicio de Medicina Interna, Hospital Alvaro Cunqueiro-Complejo Hospitalario Universitario de Vigo, Universidad de Santiago de Compostela, Vigo, Spain
10. Service de Médecine Interne, Hôpital Claude Huriez, Université de Lille, Lille, France
11. Department of Rheumatology, University of Zagreb, Zagreb, Croatia
12. Department of Pediatrics, Jaslok Hospital, Mumbai, India
13. Interdisciplinary Uveitis Center, Universitat Klinikum Heidelberg, Heidelberg, Germany.  
\* Dr Mackensen is included as a co-author posthumously, in recognition of her substantial contributions to the content of this manuscript.
14. Unidad de Reumatología Pediátrica, Hospital La Paz, Madrid, Spain
15. Pediatric Rheumatology, Hospital Universitario Valle de Hebron, Barcelona, Spain
16. Servicio de Reumatología, Hospital de Gran Canaria Dr Negrin, Las Palmas, Spain
17. Instituto de Puericultura e Pediatria Martagao Gesteira (IPPMG), Universidade Federal de Rio de Janeiro, Rio de Janeiro, Brasil
18. Department of Pediatric Rheumatology, Hacettepe University Faculty of Medicine, Ankara, Turkey
19. Pédiatrie-Néphrologie, Médecine Interne et Hypertension, Hôpital des Enfants, Toulouse, France
20. Department of Pediatric Rheumatology, Bristol Royal Hospital for Children, Bristol, UK
21. Service of Immunology/Rheumatology, Hospital de Pediatria Garrahan, Buenos Aires, Argentina
22. Pediatric Rheumatology, Institute of Rheumatology, Belgrade, Serbia
23. Division of Allergy/Immunology/Rheumatology, Department of Pediatrics, University of Florida, Gainesville, Florida, USA
24. Pediatric Clinic, Centre Hospitalier de Luxembourg, Luxembourg, Luxembourg
25. Division of Pediatrics, Department of Pediatric Immunology and Rheumatology, UMC Utrecht, Utrecht, The Netherlands
26. Pattern Recognition Receptor Discovery Performance Unit, Immuno-inflammation Therapeutic Area, GlaxoSmithKline, Collegeville, Pennsylvania, USA
27. Department of Immunology-CDB, Hospital Clinic – IDIBAPS, Barcelona, Spain
28. Pediatrics, Nemours/Alfred I. duPont Hospital for Children, Wilmington, DE, USA
29. Department of Pediatric Rheumatology, Catholic University of Leuven (KU Leuven), Leuven, Belgium

Supplemental material available at AJO.com.

Short title: Blau uveitis, a prospective multicenter case series.

Corresponding author:

Inge L. Sarens, Department of Ophthalmology, UZ Leuven Gasthuisberg, Herestraat 49, 3000 Leuven, Belgium.

E-mail: inge.sarens@uzleuven.be

Phone number: +32 16 33 26 87

Fax: +32 16 34 39 81

## Introduction

Blau syndrome is a rare, potentially debilitating, dominantly inherited prototypic autoinflammatory disease<sup>1</sup>. The Blau phenotype results from mutations in or near the nucleotide oligomerization domain of the NOD2 pattern recognition receptor. A typical clinical triad of arthritis, dermatitis and uveitis is characteristic. However, systemic features including vasculitis and involvement of various organ systems have become widely recognized<sup>2, 3</sup>. Whilst ocular involvement in Blau syndrome is a predominant feature, to date the extent of involvement or severity of inflammation has not been prospectively evaluated in a substantial number of patients. Following the initial report by Edward Blau where three members of the family displayed persistent bilateral granulomatous iritis, with or without posterior segment inflammation requiring oral corticosteroid therapy, further reports have documented a wide-ranging ocular involvement<sup>4</sup>. For example, the frequency of bilateral panuveitis ranged from 33 to 94%, often associated with chronic multifocal choroiditis<sup>1, 5, 6</sup>. A more recent detailed study of 17 eyes displayed optic nerve head involvement as a consistent finding<sup>7</sup>. Limitations of reports to date include small case series or studies, lack of longitudinal data including outcome and severity and retrospective data analysis. Therefore, many aspects of the disease, including ocular involvement and disease evolution remain elusive<sup>2</sup>.

The data presented here are derived from analysis of 50 Blau patients included in an on-going 5-year multicenter, prospective interventional case series aimed at investigating the evolution of clinical manifestations of Blau syndrome<sup>2</sup>. Here we present a cross-sectional analysis of the Blau ocular phenotype of 50 patients at baseline study visit. We also present interim data of follow-up clinical details of patients (30 patients at year 1, 19 patients at year 2 and 13 patients at year 3) to document and present disease progression and cumulative ocular damage.

Our study describes the high frequency and severity of Blau uveitis and highlights the need for close ophthalmologic surveillance as well as a search for more effective therapies.

## Patients and methods

### Patient inclusion

Ophthalmological data were collected from 50 Blau patients included in a 5-year multicenter, prospective interventional case series on articular, functional, ophthalmological, therapeutic and radiological data<sup>2</sup>. Investigators who participated in the Paediatric Granulomatous Arthritis International Registry and members of paediatric rheumatology societies were invited to join in this prospective study. Ethics committee or institutional review board approval was obtained at the coordinating centre (University of Leuven) and all participating sites (25 sites, 1-7 patients per site). All patients with a clinical diagnosis of Blau syndrome based on any (combination of) Blau clinical triad features, and proven NOD2 mutations from each site were included after written informed consent had been obtained. One patient was later excluded because his genetic NOD2 variant was not considered pathogenic

on secondary analysis. Patient inclusion commenced in 2011. The recruitment target of 50 patients was completed in February 2016 and for each patient data capture continues annually for a total of 5 years. The results presented in this report include baseline data from 50 patients at 25 centers worldwide, and follow-up data from patients followed for 1, 2 and 3 years at the time of completed enrollment. At that time, there were insufficient data to report years 4 and 5 of follow-up.

### Data Capture

A standardized ophthalmologic data collection form was used by the ophthalmologist at the participating centers (supplemental material on AJO.com). At baseline clinic visit, historical data were also recorded to capture date including onset of eye involvement and where possible detail of classification of uveitis, ocular complications and previous treatments (medical and/or surgical). At each visit, the ophthalmologist recorded uveitis laterality, graded uveitis activity based on the anatomical SUN classification and reported uveitis descriptors as developed by the SUN working group (onset, duration, course)<sup>8</sup>. Current treatment (topical and systemic) was recorded. Best corrected visual acuity was measured with the ETDRS chart (adults) or Kay Pictures (children) for distance and near. Visual acuity data per eye were evaluated against key thresholds, as defined by the SUN working group<sup>8</sup>. Visual impairment was defined according to the WHO guidelines (best-corrected visual acuity in best eye)<sup>9</sup>. No or mild visual impairment was defined by a logMAR from 0.0-0.5 (Snellen 20/20 – 20/60), moderate visual impairment from 0.5-0.9 (20/60 – 20/200), severe visual impairment from 0.9-1.3 (20/200 – 20/400), and blindness from >1.3 (>20/400). Anterior segment cells and flare were recorded per SUN classification. Active anterior chamber inflammation was defined as grade 0.5+ or more. Vitreous haze was noted and visibility recorded based on the Nussenblatt chart<sup>10</sup>. Fundal findings were recorded, and lesions were characterized as either active or inactive (scars) based on the clinical judgment (qualitative) by the treating ophthalmologist. Furthermore, sequelae of both anterior and posterior segment inflammation and intra-ocular pressure were recorded. Elevated intra-ocular pressure was defined as eye pressure greater than 24 mmHg on applanation tonometry and/or treatment with glaucoma medication<sup>8</sup>. Finally, the local ophthalmologist was asked to give an overall subjective grading of eye disease severity (mild, moderate or severe) based on their own judgment and taking into consideration visual acuity, structural and other complications, and treatment.

### Statistics

Descriptive statistics were used for demographic and clinical findings. To determine statistical significance with respect to parameters of inflammation, Fisher's exact test was employed. The influence of disease duration on severity of uveitis, was tested using logistic regression. Differences in uveitis severity in relation to gender or familial occurrence were analysed using chi-squared test. Visual acuity data were analysed using Kaplan-Meier curve for best and worst eye separately. Differences in

rate of visual acuity loss between mutations were tested with log Rank test. Analyses were performed with STATISTICA v12 software (Statsoft, Inc, Tulsa, OK).

## Results

### Demographics and genetics

Fifty patients from 25 centres across Europe, the United States, Canada, Latin-America and Asia were included in the study. Eighteen patients carried heterozygous p.R334W *NOD2* mutations, 13 heterozygous p.R334Q mutations, 4 heterozygous p.R587C mutations and the remaining 14 patients a variety of different *NOD2* mutations (T605P, M513A, M514T, M513T, G481D, G464W, E383K, E383D + D390V, Y563S, C495Y and A755V). One patient was excluded upon retesting of his genetic sample (see Methods section). Data from 49 patients (24 female, 25 male) were analysed. Table 1 gives an overview of patient and ocular clinical characteristics at baseline. In this case series, 31 patients (63%) manifested all three typical features of Blau syndrome. No patients had isolated uveitis, while 4 patients (8%) showed only skin manifestations and 4 other patients (8%) had only joint manifestations. A combination of skin and joint involvement was seen in 3 patients (6%), skin and eye involvement in 3 patients (6%), joint and eye involvement in 4 patients (8%). The median age at baseline was 205 months (range 21 – 667), 27 patients (55%) were younger than 18 years of age. The median age at onset of eye involvement was 60 months (range 6 -575). Median age at onset of skin and joint involvement was 15 (range 2-276) and 24 months (range 3 – 612), preceding eye involvement by a median of 45 and 36 months respectively. The median duration of eye disease at baseline visit was 145 months, while median skin and joint involvement at baseline was 190 and 181 months. Thirty patients had the sporadic form of the disease, while 20 patients belonged to 9 distinct Blau pedigrees. There was no difference in occurrence of panuveitis between male and female patients (Chi-squared test,  $p=0.6$ ) or between sporadic and familial cases (Chi-squared test,  $p=0.3$ ).

### Ocular involvement

Of the 38 patients with ocular involvement at baseline study visit, 37 (97%) had bilateral uveitis. Of these 75 affected eyes, 22 presented with anterior uveitis only (29%), while 38 had panuveitis (51%). In the remaining 15 eyes, a combination of anterior and/or intermediate or posterior uveitis was diagnosed. In total, the anterior segment was involved in 99% of eyes, the intermediate and posterior segments in 65% and 56% respectively. Follow up data for 6 of 11 patients with no ocular involvement at baseline, showed no development of uveitis after 1 year (1 patient), 2 years (1 patient) and 3 years (4 patients) respectively.

Logistic regression analysis showed that duration of eye disease is an important factor to predict the presence of panuveitis in the patient, with a longer duration being associated with the presence of panuveitis ( $p=0.01$ ).

At the time of this report (February 2016) follow-up data were available for 47, 30 and 18 affected eyes at year 1, 2 and 3 respectively.

### Ocular Inflammation and ocular complications

At baseline, optic disc changes were described in 22 eyes (29%), comprising pallor in 9 eyes (12%), peripapillary nodules in 9 eyes (12%) and edema in 4 eyes (5%). Macular edema was noted in 8 eyes (11%), only occurring in eyes presenting with panuveitis. The most commonly described fundus change were multifocal chorioretinal lesions in 29 eyes (39%). Chorioretinal disease was active in 4 out of 75 eyes at baseline visit (5%). No active vasculitis was described (Table 2). Figure 1 shows typical ophthalmological features observed in our patient population.

We undertook an interim analysis as documented in Figure 2 to demonstrate our early findings with respect to evolution of inflammatory parameters from baseline over a 3-year period. Despite all patients receiving prolonged topical and systemic treatment (at individual physicians discretion), there was no significant decrease of inflammatory activity at yearly visits (Fisher's Exact test). Table 2 shows the prevalence of optic disc and chorioretinal changes at follow-up visits. Macular edema was noted in 8 – 16% of eyes during follow-up. Chorioretinal lesions remained the commonest abnormality and recorded in 43 eyes (50%). At follow-up, active choroiditis was noted in 5 eyes (10%).

Uveitis complications in the anterior segment were also common. Band keratopathy was noted in 16 patients (21%), posterior synechiae in 34 patients (45%) and cataract in 41 patients (55%) at baseline visit (table 2). With follow-up, the prevalence of these complications remained unchanged. At baseline visit, 19 eyes (25%) had elevated intra-ocular pressure. During follow-up, 10, 5 and 3 patients (9%, 17% and 17%) at years 1, 2, and 3 respectively were reported to have elevated intra-ocular pressure.

### Medication

At baseline visit, 56 out of 75 eyes were on topical corticosteroids (75%). Topical anti-glaucoma medication was used in 12 eyes (16%) and 10 eyes were on mydriatic agents to prevent the formation of posterior synechiae (13%). Thirty-seven of the 38 patients with ocular involvement, were treated with systemic medication with 68% receiving a combination of systemic corticosteroids with immunosuppressive drugs and/or biologicals. Within these combinations, systemic corticosteroids were the most commonly used (26 patients), followed by methotrexate (18 patients), adalimumab (17 patients), infliximab (5 patients), mycophenolate mofetil (3 patients), thalidomide (2 patients) or canakinumab (1 patient). Choice of immunosuppressants differed among the participating centers, and therefore efficacy was difficult to ascertain. Eight patients were reported to have insufficient disease control with methotrexate. Six patients had insufficient disease control with etanercept. Two patients experienced an adverse drug reaction to infliximab infusion, leading to discontinuation of the drug. No other major side-effects were reported.

### Visual acuity

Data on visual acuity were available for 66 eyes at baseline and for 40, 28 and 16 eyes for years 1, 2 and 3 respectively. Table 3 shows data on visual acuity at baseline visit and during follow-up. Using WHO criteria for visual impairment, 21% of patients experienced moderate visual impairment at baseline visit.

Determining visual acuity loss during follow-up, when assessing the best eye, there was a trend over the course of three years for further visual loss. By year 3, there was a cumulative decrease in visual acuity of the best eye of 33% (Kaplan-Meier regression analysis; Figure 3).

When we compared the rate of visual acuity loss among subgroups with different NOD2 mutations, it was noted that patients with p.R334W and p.R334Q mutations had less visual acuity loss compared to patients with all other genetic variants combined ( $p=0.04$ , LogRank test). A sub-analysis comparing p.R334W versus p.R334Q did not show a significant difference.

### **Discussion**

Ocular involvement is one of the three main clinical features of Blau syndrome. We here report data on the ocular phenotype at baseline study visit and present interim follow-up data from the first multicenter, international prospective case series on the evolution of Blau uveitis in 50 patients. To the best of our knowledge, and based on computerized literature search, our case series represents the largest group of patients prospectively studied. We found that active anterior and posterior uveitis persists over time in more than half of the patients despite combined topical and systemic therapy. In this group, there was a high rate of ocular complications (macular edema, raised intraocular pressure and cataract) alongside a progressive decrease in visual acuity. More than 25% of patients suffered moderate to severe visual impairment. Our findings confirm the high morbidity of Blau syndrome uveitis, as previously described<sup>5,7,11,12,13</sup>.

The hallmark finding in Blau syndrome uveitis is a chronic bilateral panuveitis with multifocal chorioretinal lesions and our prospective study showed that more than half of patients had panuveitis at baseline visit, and particularly more frequently in patients with a longer disease duration ( $p=0.01$ , simple logistic regression). These results confirm in a more robust data set and data capture findings from previous studies with panuveitis ranging from 33% to 94% dependent on the study<sup>2,6,7</sup>.

Recently, a detailed study on 17 eyes showed a distinctive nodular peripapillary appearance in 76% of eyes, alongside chronic bilateral panuveitis. It was postulated that these peripapillary nodular excrescences could be related to granulomatous inflammation at the level of the optic nerve head<sup>7</sup>. Another prior study showed peripapillary granulomas to be present in one patient<sup>14</sup>. However this series shows that optic disc abnormalities were only noted in 39% of patients at baseline, ranging from optic nerve head pallor, edema and only in 12% of eyes were peripapillary nodules noted. Of note: there may be an underestimate of the prevalence of optic nerve findings as study methodology did not require fundus photographs and reading centre assessment.

Patients with Blau syndrome may be misdiagnosed initially as juvenile idiopathic arthritis (JIA). Although both diseases show some overlapping features, there are clear distinctions in uveitis phenotype, severity of inflammation and ocular disease progression. On comparing the data from our study with patients with JIA-uveitis, a number of differences are illuminated<sup>15, 16, 17</sup>. For example, uveitis is seen in 10-20% of JIA patients, and almost exclusively involves the anterior segment. In our Blau patients, uveitis was seen in 76% of patients with frequent intermediate and posterior involvement. Although complications of anterior eye involvement in JIA are not uncommon, the long-term outcome of visual function has a better prognosis. In a study of more than 1000 JIA patients, only 9% of eyes had visual acuity worse than 0.3 logMAR (Snellen 20/40) after a mean follow-up of 6.3 years<sup>15</sup>. In comparison, at baseline visit, 27% of the eyes presented with visual acuity worse than 0.3 logMAR (20/40). In addition, Blau syndrome is characterized by a persistently active panuveitis, which may explain the higher rate of complications leading to more cumulative damage and a less favourable visual outcome.

Our study also highlights the variety and extent of therapies among centers, which is not unexpected given the lack of international therapeutic guidelines and evidence of therapeutic effectivity in Blau uveitis. Although currently we only have interim follow-up data alongside the retrospective data collection, including treatment and duration of uveitis and extent of uveitis at baseline assessment, we note a high prevalence of persistent uveitis activity despite systemic steroid, immune modulating and biologic treatments. An interesting observation is the possible value of IL-1 inhibition in treatment resistant Blau syndrome<sup>6, 14</sup>. One of these patients is included in the current series.

Okafuji et al suggested an association between visual impairment and the 2 most frequent NOD2 genotypes<sup>18</sup>. In our study, patients with these p.R334W or p.R334Q genotypes had a significantly slower rate of visual acuity loss compared to other mutations combined. A sub-analysis of p.R334W versus p.R334Q did not reach statistical significance. The role of NOD2 genotyping to predict visual outcome in patients with Blau syndrome is still unclear.

We acknowledge that the study design imposed limits in the degree of detail in the description of the Blau syndrome ocular phenotype. A standardized data collection form (available as supplemental material from AJO.com) was used; we relied on the expert judgment of the local ophthalmologists to complete this. Because no standardized description variables were used to describe specific fundus changes, information on some phenotypic details may have been lost. Our study included only yearly visits, thereby precluding the recording of possible intra-year fluctuations. The high rates of active ocular inflammation observed at the yearly evaluations however, are consistent with an unrelenting and unremitting pattern in Blau uveitis. Imaging techniques to assess posterior eye disease and optic nerve involvement are evolving rapidly, but were not widely available at the time of study design (2010) and so not included in this study. Additional imaging examinations in a future study will be of interest to even better define phenotypic details of Blau uveitis. For statistical analysis, we did not consider clustering within families, due to the small sample size, although data collection for this study is still ongoing and full 5-year data will be reported duly. Notwithstanding, this study provides cross-sectional data and importantly, interim follow-up analysis given the prevalence of on-going inflammation. The data at this stage demonstrate that uveitis activity, complications and visual acuity loss are persistent.

In conclusion, Blau syndrome is associated with severe ocular morbidity. Ophthalmic features in the classical triad are usually the last to manifest. Our findings further demonstrate that despite maximal local treatment and additional systemic immunosuppression (albeit varied between centers), disease activity is insufficiently controlled in this group. Advances in the understanding of downstream effects of NOD2 mutations will likely contribute to the development of effective targeted therapies.

**Acknowledgments / disclosure**

- a. **Funding/support:** This work was supported in part by an unrestricted grant from GlaxoSmithKline awarded to C.W.
- b. **Financial disclosures:** C.D.R. was awarded a grant to Study Blau Syndrome from the University of Leuven. J.B. is an employee of GlaxoSmithKline with stock ownership. C.H.W. received an unrestricted grant from GlaxoSmithKline to carry out the work described here. F.M. has received lecture honoraria from Heidelberg Eng, MSD; has provided consultancy services for Merck Serono and Abbvie; and has received grants/ research support from Allergan, Santen, Servier and AbbVie. All other authors have declared no conflicts of interest.
- c. **Acknowledgments :** We wish to express our gratitude to our colleagues ophthalmologists for their collection of and contribution with clinical data on the Blau patients reported in this study, to Ms Aniko Lovik, Leuven Biostatistics and Statistical Bioinformatics Centre (L-BioStat), KU Leuven for statistical support, to Ms Anne Maes, MBS, UZ Leuven, for excellent administrative support, and to Janice Connor, GlaxoSmithKline, for her logistical contribution to the Blau cohort project. We are grateful to all patients and families for allowing us to use their clinical information.

## References

1. Caso F, Costa L, Rigante D, et al. Caveats and truths in genetic, clinical, autoimmune and autoinflammatory issues in Blau syndrome and early onset sarcoidosis. *Autoimmun Rev* 2014 ; 13(12) : 1220-9.
2. Rosé CD, Pans S, Casteels I, et al. Blau syndrome: cross-sectional data from a multicentre study of clinical, radiological and functional outcomes. *Rheumatology* 2015 ; 54(6) : 1008-16.
3. Rose CD, Martin TM, Wouters CH. Blau syndrome revisited. *Curr Opin Rheumatol* 2011 ; 23(5) : 411-8.
4. Blau EB. Familial granulomatous arthritis, iritis, and rash. *J Pediatr* 1985 ; 107(5) : 689-93.
5. Latkany PA, Jabs DA, Smith JR, et al. Multifocal choroiditis in patients with familial juvenile systemic granulomatosis. *Am J Ophthalmol* 2002 ; 134(6) : 897-904.
6. Arostegui JI, Arnal C, Merino R, et al. NOD2 gene-associated pediatric granulomatous arthritis : clinical diversity, novel and recurrent mutations, and evidence of clinical improvement with Interleukin-1 blockade in a Spanish cohort. *Arthritis Rheum* 2007 ; 56(11) : 3805-3813.
7. Carreno E, Guly CM, Chilov M, et al. Optic nerve and retinal features in uveitis associated with juvenile systemic granulomatous disease (Blau syndrome). *Acta Ophthalmol* 2015 ; 93(3) : 253-7.
8. SUN working group. Standardization of uveitis nomenclature for reporting clinical data. Results of the first international workshop. *J Ophthalmol* 2005 ; 140 : 509-16.
9. Dandona L, Dandona R. Revision of visual impairment definitions in the International Statistical Classification of Diseases. *BMC Med* 2006 ; 4 : 7.
10. Nussenblatt RB, Palestine AG, Chan CC, et al. Standardization of vitreal inflammatory activity in intermediate and posterior uveitis. *Ophthalmology*. 1985;92(4):467–471.
11. Kurokawa T, Kikuchi T, et al. Ocular manifestations in Blau syndrome associated with a CARD15/NOD2 mutation. *Ophthalmology* 2003 ; 110 : 2040-4.
12. Jabs DA, Houk JL, Bias WB, et al. Familial granulomatous synovitis, uveitis and cranial neuropathies. *Am J Med* 1985 ; 78(5) : 801-4.
13. Snyers B, Dahan K. Blau syndrome associated with a CARD15/NOD2 mutation. *Am J Ophthalmol* 2006 ; 142 : 1089-92.
14. Simonini G, Zhaohui X, Caputo R, et al. Clinical and transcriptional response to the long-acting interleukin-1 blocker canakinumab in Blau syndrome-related uveitis. *Arthritis Rheum* 2013 ; 65(2) : 513-518.
15. Saurenmann RK, Levin AV, Feldman BM, et al. Prevalence, risk factors, and outcome of uveitis in juvenile idiopathic arthritis: a long-term follow-up study. *Arthritis Rheum* 2007 ; 56(2) : 647-57.
16. Grassi A, Corona F, Casellato A, et al. Prevalence and outcome of juvenile idiopathic arthritis-associated uveitis and relation to articular disease. *J Rheumatol* 2007 ; 34(5) : 1139-45.
17. Heiligenhaus A, Minden K, Föll D, Pleyer U. Uveitis in juvenile idiopathic arthritis. *Dtsch Arztebl Int* 2015 ; 112(6) : 92-100.
18. Okafuji I, Nishikomori R, Kanazawa N, et al. Role of the NOD2 genotype in the clinical phenotype of Blau syndrome and early-onset sarcoidosis. *Arthritis Rheum* 2009 ; 60 : 242-250.

## Figure captions

### Figure 1 :

**Fundus pictures showing features of Blau Syndrome uveitis. Pictures on the top show the right eye of a Blau patient with panuveitis. Pictures on the bottom show the left eye of a different Blau patient with panuveitis.**

**Top left:** Widefield fundus picture of right eye, showing multiple chorioretinal scars in the inferior retina. The optic disc is pale and has a nodular border, more detailed in the top right picture.

**Top right:** Optic disc fundus picture of right eye, showing a pale optic disc with a nodular border and inferior chorioretinal scars.

**Bottom left:** Widefield fundus picture of the left eye showing multiple chorioretinal scars and a nodular border around the optic disc,

**Bottom right:** Optic disc fundus picture of left eye, showing peripapillary nodules around the border of the optic disc. Multiple chorioretinal scars and a macular scar are also visible.

(courtesy of dr C. Guly, Bristol Eye Hospital, Bristol UK)

### Figure 2 :

**Evolution of inflammatory features in Blau uveitis at baseline and during follow-up.**

Data are expressed as percentages of eyes with ocular involvement (75 eyes at baseline, 47 eyes at year 1, 30 eyes at year 2, and 18 eyes at year 3).

Presence of AC cells was defined as grade  $\geq 0.5$  and AC flare as grade  $\geq 1$  according to SUN classification; vitreous haze as grade  $\geq 1$  according to Nussenblatt classification. AC: anterior chamber.

### Figure 3:

**Visual acuity loss in Blau uveitis during disease course.**

Kaplan Meier regression analysis for the best eye showing survival rates of 0.9, 0.8 and 0.67, after 1, 2 and 3 years of follow-up, respectively. In a sub-analysis, the rate of visual acuity loss proved to be significantly lower in patients with R334W or R334Q mutation (survival rates of 0.97, 0.9 and 0.72), compared to patients with all other mutations combined (survival rates of 0.7 and 0.5, no year 3 data available) ( $p=0.04$ ).

**Table 1: Characteristics of Blau syndrome patients at baseline visit.**

Patient-specific characteristics (number of patients, percentage)						
Number of patients	49					
Gender, male	25 (51.1%)					
Familial form	20 (40.8%)					
NOD2 genotype, R334W	18 (36.7%)					
NOD2 genotype, R334Q	13 (26.5%)					
NOD2 genotype, other	18 (36.7%)					
Median age at diagnosis of arthritis, in months (range)	24 (3-612)					
Median age at baseline visit, in months (range)	205 (21-667)					
Number of patients with eye disease	38					
Bilateral uveitis	37 (97.3%)					
Median age at diagnosis of uveitis, in months (range)	60 (6-575)					
Median duration of eye disease at baseline, in months (range)	145 (5-638)					
Therapies						
Oral corticosteroids	26 (68.4%)					
Methotrexate	18 (47.4%)					
Biologicals	25 (65.8%)					
Eye-specific characteristics (number of eyes, percentage)						
Number of affected eyes	75					
Panuveitis	38 (50.7%)					
Topical corticosteroids	56 (74.7%)					
Topical anti-glaucoma medication	12 (16.0%)					
Inflammatory activity (n=75)	0+	0.5+	1+	2+	3+	4+
AC cells (SUN grading)	43 (57.3%)	9 (12.0%)	13 (17.3%)	8 (10.7%)	1 (1.3%)	1 (1.3%)
AC flare (SUN grading)	53 (70.7%)	2 (2.7%)	12 (16.0%)	8 (10.7%)	0	0
Vitreous haze (Nussenblatt chart)	41 (54.7%)	8 (10.7%)	15 (20.0%)	7 (9.3%)	3 (4.0%)	1 (1.3%)
Visual acuity (n=66)						
20/20 or better	20 (30.3%)					
20/25 – 20/40	28 (42.4%)					
20/50 – 20/150	12 (18.2%)					
20/200 or worse	6 (9.1%)					

**Table 2: Prevalence of inflammatory features and complications of Blau Syndrome uveitis at baseline and follow-up visits.**

Inflammatory features and complications noted at baseline and during follow-up are shown for anterior and posterior segment respectively. Data for each feature are expressed as number (percentage) of affected eyes.

<sup>a</sup>AC = Anterior Chamber. AC cells and flare recorded according to SUN classification. Vitreous haze recorded with Nussenblatt chart.

<sup>b</sup>Optic disc changes included optic disc pallor or peripapillary nodules.

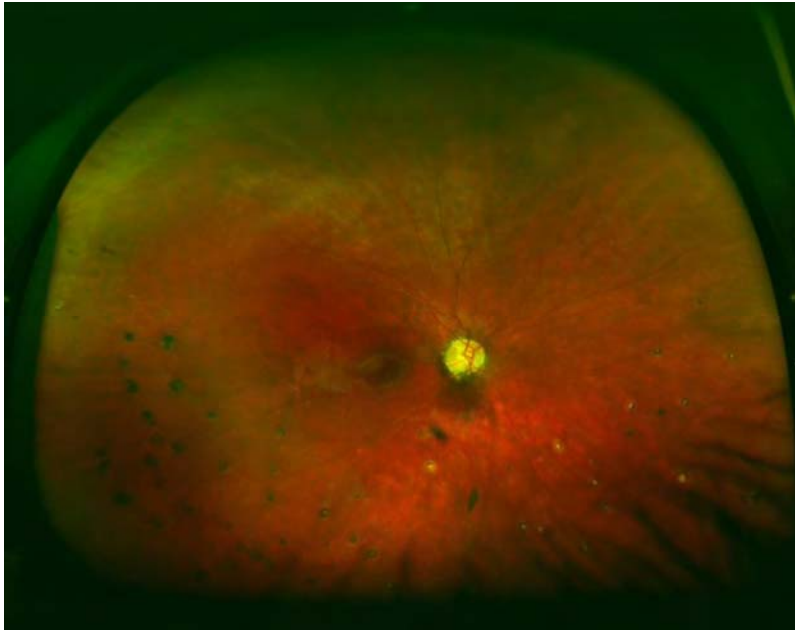
<sup>c</sup>Chorioretinal changes comprised multifocal chorioretinal lesions, both active and inactive.

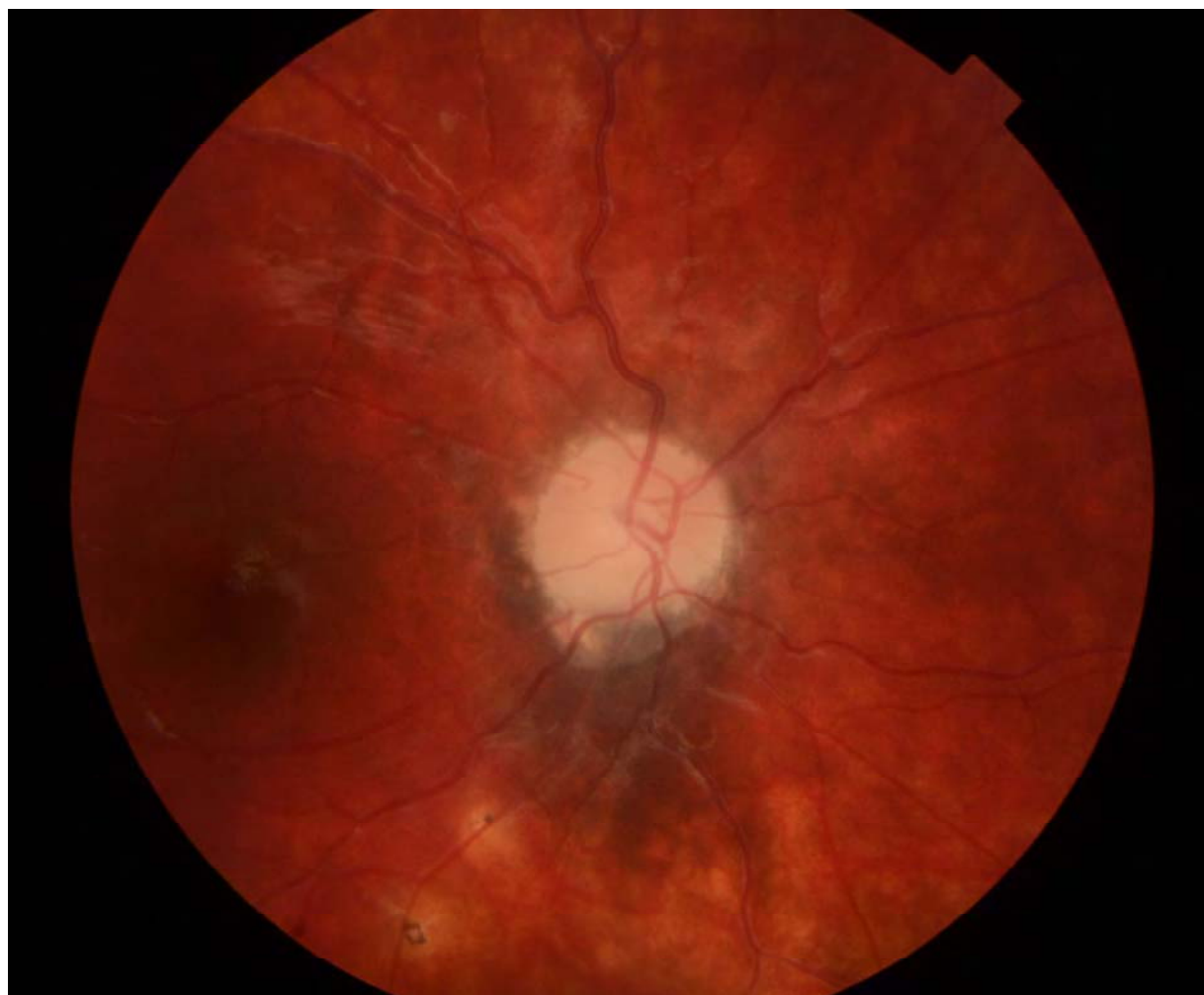	<b>Baseline (n=75)</b>	<b>Year 1 (n=47)</b>	<b>Year 2 (n=30)</b>	<b>Year 3 (n=18)</b>
<b>Anterior segment</b>				
Active AC inflammation <sup>a</sup>				
AC cells ( $\geq 0.5$ )	30 (40.0%)	16 (34.0%)	17 (56.7%)	11 (61.1%)
AC flare ( $\geq 1$ )	16 (21.3%)	9 (19.1%)	6 (20.0%)	3 (16.7%)
Keratic Precipitates	25 (33.3%)	18 (38.3%)	13 (43.3%)	11 (61.1%)
Band keratopathy	16 (21.3%)	9 (19.1%)	6 (20.0%)	8 (44.4%)
Posterior synechiae	34 (45.3%)	23 (48.9%)	14 (46.7%)	7 (38.9%)
Cataract	41 (54.6%)	25 (53.2%)	17 (56.7%)	10 (55.6%)
<b>Posterior segment</b>				
Vitreous haze ( $\geq 1$ )	32 (42.7%)	18 (38.3%)	16 (53.3%)	9 (50.0%)
Active choroiditis	4 (5.3%)	4 (8.5%)	0	2 (11.1%)
Active vasculitis	0	1 (2.1%)	0	2 (11.1%)
Macular edema	8 (10.7%)	4 (8.5%)	3 (16.7%)	3 (16.7%)
Optic disc changes <sup>b</sup>	22 (29.3%)	14 (29.8%)	6 (20.0%)	6 (33.3%)
Chorioretinal changes <sup>c</sup>	29 (38.7%)	20 (42.6%)	13 (43.3%)	9 (50%)
Retinal detachment	3 (4.0%)	1 (2.1%)	0	1 (5.6%)

**Table 3: Visual acuity in Blau Syndrome patients at baseline and follow-up.**

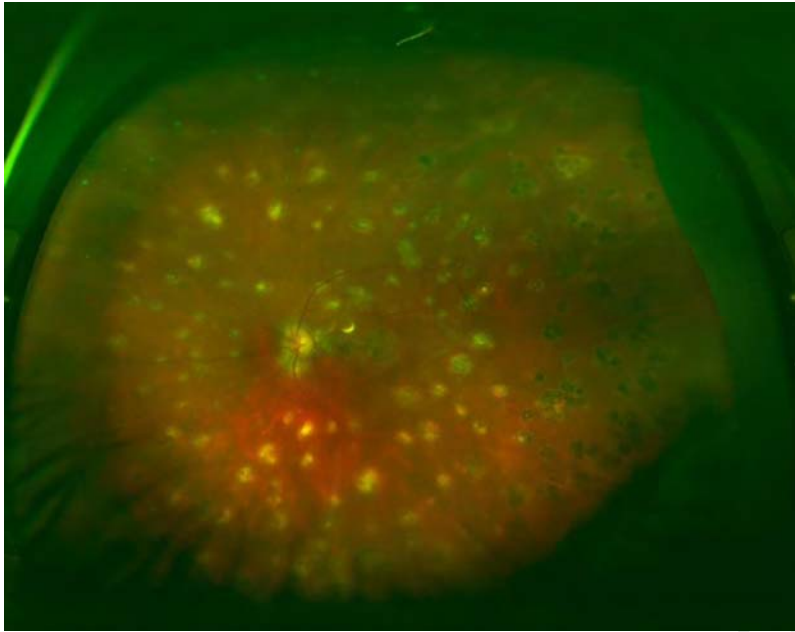
Visual acuity (VA) was recorded, using ETDRS for adults and Kay Pictures for children. Median logMAR (and Snellen) values are shown in rows 1 and 2, with the total range between brackets. Rows 3 and 4 depict prevalence of visual acuity loss to thresholds according to SUN classification recommendations.

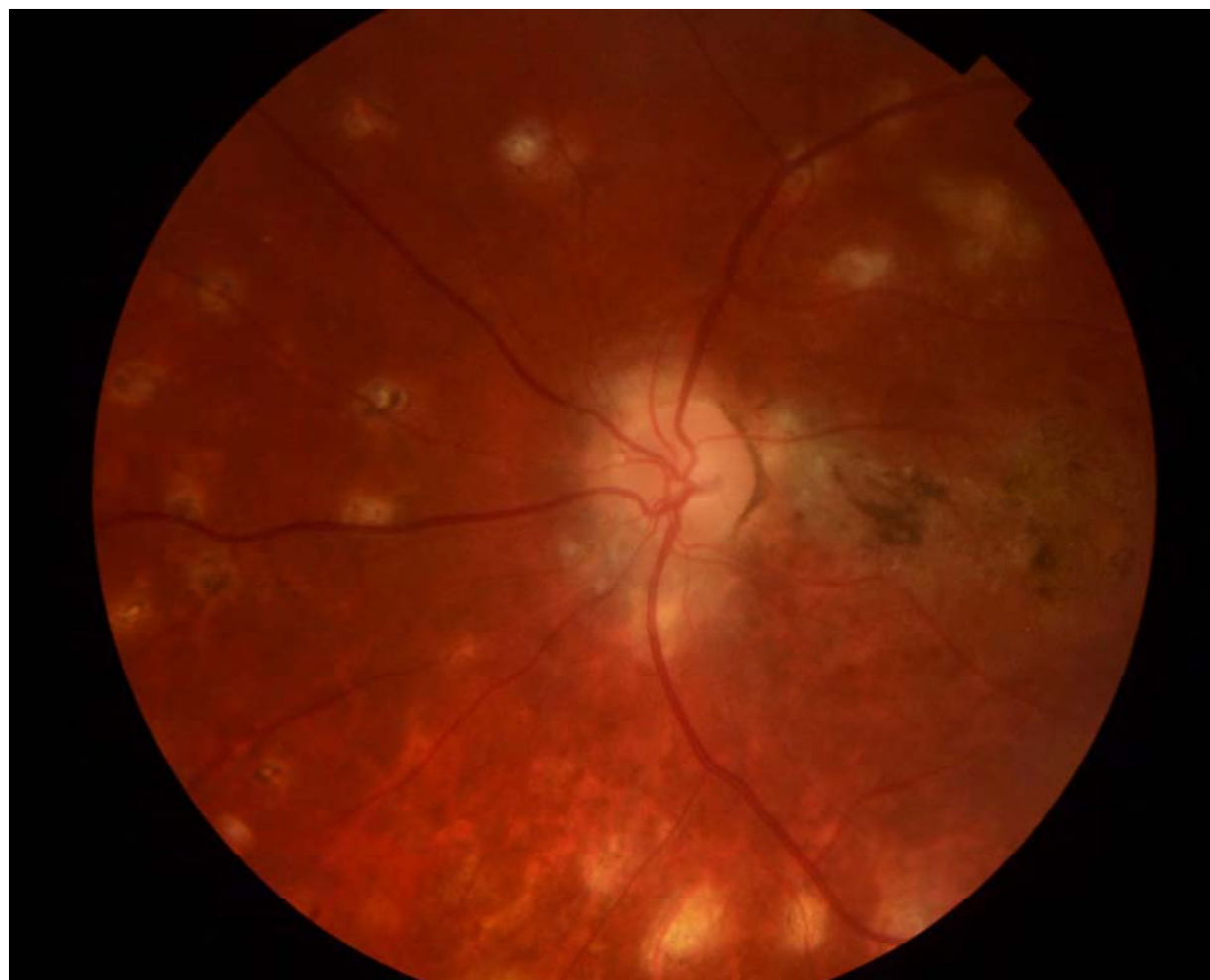	<b>Baseline (n=66)</b>	<b>Year 1 (n=40)</b>	<b>Year 2 (n=28)</b>	<b>Year 3 (n=16)</b>
<b>Median VA</b>	0.1 (20/25)	0.1 (20/25)	0.075 (20/25)	0.2 (20/30)
<b>Range of VA</b>	0 – 1.3 (20/20 – 20/400)	0 – 1.3 (20/20 – 20/400)	0 – 1.1 (20/20 – 20/200)	0 – 1 (20/20 – 20/200)
<b>n (%) of eyes with VA <math>\geq</math> logMAR 0.4 (<math>\leq</math>20/50)</b>	18 (27.3%)	11 (27.5%)	7 (25.0%)	5 (31.3%)
<b>n (%) of eyes with VA <math>\geq</math> logMAR 1 (<math>\leq</math> 20/200)</b>	6 (9.1%)	6 (15.0%)	2 (7.1%)	2 (12.5%)





ACCEPTED





ACCEPTED

