

Neuroprotective effects of thymoquinone against spinal cord ischemia-reperfusion injury by attenuation of inflammation, oxidative stress, and apoptosis

Emre Cemal Gökce, MD,¹ Ramazan Kahveci, MD,² Aysun Gökce, MD,³ Berker Cemil, MD,¹ Nurkan Aksoy, MD,⁴ Mustafa Fevzi Sargon, MD, PhD,⁵ Üçler Kısa, MD,⁴ Bülent Erdoğan, MD,¹ Yahya Güvenç, MD,⁶ Fatih Alagöz, MD,⁷ and Ozan Kahveci, MD⁸

¹Department of Neurosurgery, Turgut Özal University, Faculty of Medicine; ²Department of Pathology, Ministry of Health, Diskapi Yıldırım Beyazıt Education and Research Hospital; ³Department of Anatomy, Hacettepe University, Faculty of Medicine; ⁴Department of Neurosurgery, Ministry of Health, Ankara Sincan State Hospital; and ⁵Department of Neurosurgery, Ministry of Health, Ankara Numune Education and Research Hospital, Ankara; ⁶Department of Neurosurgery, Ministry of Health, Çanakkale State Hospital, Çanakkale; ⁷Department of Biochemistry, Kirikkale University, Faculty of Medicine, Kirikkale; and ⁸Department of Emergency Medicine, Faculty of Medicine, Bulent Ecevit University, Zonguldak, Turkey

OBJECTIVE Ischemia-reperfusion (I/R) injury of the spinal cord following thoracoabdominal aortic surgery remains the most devastating complication, with a life-changing impact on the patient. Thymoquinone (TQ), the main constituent of the volatile oil from *Nigella sativa* seeds, is reported to possess strong antioxidant, antiinflammatory, and antiapoptotic properties. This study investigated the effects of TQ administration following I/R injury to the spinal cord.

METHODS Thirty-two rats were randomly allocated into 4 groups. Group 1 underwent only laparotomy. For Group 2, aortic clip occlusion was introduced to produce I/R injury. Group 3 was given 30 mg/kg of methylprednisolone intraperitoneally immediately after the I/R injury. Group 4 was given 10 mg/kg of TQ intraperitoneally for 7 days before induction of spinal cord I/R injury, and administration was continued until the animal was euthanized. Locomotor function (Basso, Beattie, and Bresnahan scale and inclined plane test) was assessed at 24 hours postschemia. Spinal cord tissue samples were harvested to analyze tissue concentrations of malondialdehyde, nitric oxide, tumor necrosis factor- α , interleukin-1, superoxide dismutase, glutathione-peroxidase, catalase, and caspase-3. In addition, histological and ultrastructural evaluations were performed.

RESULTS Thymoquinone treatment improved neurological outcome, which was supported by decreased levels of oxidative products (malondialdehyde and nitric oxide) and proinflammatory cytokines (tumor necrosis factor- α and interleukin-1), increased activities of antioxidant enzymes (superoxide dismutase, glutathione-peroxidase, and catalase), as well as reduction of motor neuron apoptosis. Light microscopy and electron microscopy results also showed preservation of tissue structure in the treatment group.

CONCLUSIONS As shown by functional, biochemical, histological, and ultrastructural analysis, TQ exhibits an important protective effect against I/R injury of the spinal cord.

<http://thejns.org/doi/abs/10.3171/2015.10.SPINE15612>

KEY WORDS thymoquinone; methylprednisolone; neuroprotection; spinal cord ischemia-reperfusion injury; oxidative stress; inflammation; apoptosis; spinal cord injury; rat

ISCHEMIC spinal cord injury is a major cause of delayed paraplegia, occurring in up to 14% of patients who undergo thoracoabdominal aortic interventions.¹⁵ Low blood flow during aortic cross-clamping and the reperfusion state following the procedure induces neuronal cell injury. Injury-induced oxidative stress, inflammation, and

apoptosis are the major secondary injury mechanisms contributing to neuronal cell death and hampering the neurorepair process subsequent to the ischemia-reperfusion (I/R) state.¹⁰ Unfortunately, proven effective therapy for neuroprotection following I/R injury is presently not available.

Nigella sativa is a flowering plant known as the black

ABBREVIATIONS BBB = Basso, Beattie, and Bresnahan; CAT = catalase; ELISA = enzyme-linked immunosorbent assay; GSH-Px = glutathione-peroxidase; IL-1 = interleukin-1; IP = inclined plane; IQR = interquartile range; I/R = ischemia-reperfusion; MDA = malondialdehyde; MP = methylprednisolone; NO = nitric oxide; SOD = superoxide dismutase; TNF α = tumor necrosis factor- α ; TQ = thymoquinone.

SUBMITTED May 26, 2015. **ACCEPTED** October 6, 2015.

INCLUDE WHEN CITING Published online February 12, 2016; DOI: 10.3171/2015.10.SPINE15612.

seed and is commonly used as a natural food additive. Traditionally, these seeds have been used for the prevention and cure of many ailments in the Middle East and Southeast Asia; in recent years, this annual herb has gained more interest for potential medical use.³ *N. sativa* has been shown to be rich in polyunsaturated fatty acids³⁰ and phospholipids and contains a number of active ingredients, such as thymoquinone (TQ), hydro-TQ, and nigelone.⁴⁶ The active ingredients of *N. sativa* have beneficial effects against many diseases, including inflammation, hypertension, diabetes, headache, fever, and gastrointestinal disturbances.⁴

Modern pharmacological and toxicological studies have demonstrated that TQ, the most abundant and bioactive constituent of oil extract of *N. sativa*, exerts antioxidant effects,²⁷ antiinflammatory effects,¹⁶ and antitumor activity.¹⁹ There is growing interest in the therapeutic potential of TQ in different research fields. In a previous study by Hosseinzadeh et al., TQ treatment attenuated lipid peroxidation and induced a neuroprotective effect against cerebral I/R injury in rat hippocampus.²¹ Also, in experimental models of Parkinson disease and acrylamide-induced neurotoxicity in rats, TQ afforded neuroprotection partly due to the attenuation of lipid peroxidation.^{33,43} Considering such beneficial effects as those mentioned above, we investigated and evaluated the efficacy of TQ in I/R injury of the spinal cord.

Methods

Experimental Groups

The experimental protocol was performed in accordance with the guidelines of European Communities Council Directive of November 24, 1986 (86/609/EEC), on the protection of animals for experimental use. All experimental procedures were conducted with the prior approval of the animal experimental ethics committee of Ankara Education and Research Hospital. Thirty-two male Wistar albino rats with a mean age of 8 months, weighing 250 ± 30 g, were kept in polycarbonate cages. Rats were allowed free access to food and tap water. The rats were kept in cages in which the temperature was maintained at 25°C both day and night. Animals were randomly assigned into 4 groups, each consisting of 8 rats as follows.

Animals in Group 1 ($n = 8$) underwent sham operations. Rats underwent the surgical procedure but the aorta was not occluded. Nonischemic spinal cord samples were obtained after 24 hours to determine normal spinal cord morphology and baseline biochemical values.

Rats in Group 2 ($n = 8$) underwent spinal cord I/R injury, as described below. Spinal cord samples were removed 24 hours after injury. Rats received an intraperitoneal dose of 1 ml physiological saline (0.9% NaCl) as vehicle for 7 days before I/R injury induction, and administration was continued until the animal was euthanized.

Group 3 ($n = 8$), the methylprednisolone (MP) group, was similar to Group 2, but 30 mg/kg MP acetate (Mustafa Nevzat) was injected intraperitoneally immediately following aortic clamping and reperfusion.

Group 4 ($n = 8$), the TQ group, was also similar to Group 2. However, rats received 10 mg/kg/day of TQ (Sig-

ma Aldrich) intraperitoneally for 7 days before spinal cord I/R injury induction. Administration was continued until animals were euthanized.

Surgical Procedure

Spinal cord I/R was performed using the previously described method.⁵² The rats were anesthetized by an intraperitoneal injection of 10 mg/kg xylazine (Rompun; Bayer) and 50 mg/kg ketamine (Ketalar; Parke Davis), and allowed to breathe spontaneously. Body temperature was maintained at $37^\circ\text{C} \pm 0.5^\circ\text{C}$, supported with a thermal pad and a heating lamp, and continuously monitored during the surgical procedure.

The animals were placed supine. Using a transperitoneal approach, the aorta was isolated from the beginning of the left renal artery down to the aortic bifurcation. Heparin (200 U) was administered intravenously 5 minutes before occlusion. The aorta was then cross-clamped from a point just inferior to the left renal artery to the aortic bifurcation by using 2 bulldog clamps. After the occlusion, the pulsation of the femoral artery disappeared. The clamps were closed for 30 minutes because ischemic duration of less than 20–30 minutes is rarely associated with neurological deficit incidence, and when occlusion exceeds 40–60 minutes, all of the pathological reactions rise disproportionately.³² Following ischemia, clips were removed and return of the aortic pulse was verified. The wound was closed in layers after the operation.

Following the injury, bladder massage was performed twice to stimulate autonomic urinary reflex. Twenty-four hours postsurgery, after scoring neurological functions, rats were euthanized with an injection of high-dose (200 mg/kg) pentobarbital (Nembutal; Oak Pharmaceuticals). Next, spinal cord segments between L-4 and L-6 were rapidly removed and immediately extracted on ice and divided into 3 equal parts for histopathological examination, transmission electron microscopic observation, and biochemical analysis. Cranial (L-4) and middle (L-5) parts were obtained for light and electron microscopic evaluation, respectively. The caudal parts (L-6) were snap-frozen in liquid nitrogen without additives and then transferred to a tissue-archiving freezer (-80°C) and stored at -80°C until biochemical analysis.

Neurological Evaluation

The severity of hindlimb motor dysfunction after spinal cord I/R injury was determined for each animal in an open field test. A 21-point grading scale was used, according to an efficient and accurate scoring system described by Basso et al.⁹ The Basso, Beattie, and Bresnahan (BBB) locomotor rating scale is used to analyze the animal's activity in limb joints, coordination in forelimb/hindlimb movement, weight support, and trunk position, and standardizes locomotor outcome measures across laboratories. At 24 hours after reperfusion, the animals were evaluated for hindlimb motor function by an independent observer who was blinded to the protocols and the group assignment.⁹

Histopathological Evaluation

The lumbar spinal cord (L-4) was stored at 4°C in 10%

phosphate-buffered formalin for 48 hours. After dehydration in the graded ethanol, the spinal cord was embedded in paraffin. Coronal sections, each 5 μm thick, of the spinal cord (L-4 segment) were cut from the paraffin blocks using a microtome and stained with H & E.

All sections were examined under a light microscope (Olympus BH-2; Olympus Corp.) by 2 pathologists; these pathologists were blinded to the origin of the samples. Four different parameters (neuronal degeneration, cellular edema, hemorrhage/congestion, and inflammation) were analyzed for histological changes. A semiquantitative scoring system, ranging from 0 to 3, was used to grade histopathological changes as follows: 0 = normal, 1 = mild, 2 = moderate, and 3 = severe. Interrater and intrarater reliability for neuronal degeneration, cellular edema, hemorrhage/congestion, and inflammation were evaluated by calculating the coefficient of kappa (κ) and 95% CIs, with $\kappa < 0$ indicating no agreement, 0–0.20 slight, 0.21–0.40 fair, 0.41–0.60 moderate, 0.61–0.80 substantial, and 0.81–1 almost perfect agreement. The pathological score for each spinal cord was calculated by averaging the scores of these 4 parameters. The specimens of the groups with I/R injury were compared with sections of the sham group, members of which did not suffer from ischemic injury.

Degenerative and ischemic features of motor neurons were identified by shrunken cellular bodies, disappearance of Nissl granules, cytoplasmic eosinophilia, and nuclear pyknosis. According to a previously described method²³ to assess the degree of neuronal injury in more detail, the remaining normal neurons in the ischemic ventral spinal cord of each animal were counted in 3 sections selected randomly from the rostral, middle, and caudal levels of the L-4 segment and then averaged. The number of normal motor neurons per section in the anterior spinal cord (anterior to an imaginary line drawn through the central canal perpendicular to the vertical axis) was compared among these groups.

Ultrastructural Examination

For transmission electron microscopic examination, the tissue samples were fixed in 2.5% glutaraldehyde for 24 hours, washed in phosphate buffer (pH 7.4), postfixed in 1% osmium tetroxide in phosphate buffer (pH 7.4) for 2 hours, and dehydrated in increasing concentrations of alcohol. Then, the tissues were washed with propylene oxide and embedded in epoxy resin embedding media. Semithin sections (approximately 2 μm in thickness) and ultrathin sections (approximately 60 nm in thickness) were cut with a glass knife on an LKB-Nova (LKB-Produkt) ultramicrotome. The semithin sections were stained with methylene blue and examined using a Nikon Optiphot light microscope. Following this examination, the tissue blocks were trimmed, their ultrathin sections were cut using the same ultramicrotome, and they were stained with uranyl acetate and lead citrate. Following staining, all of the ultrathin sections were examined using a Jeol JEM 1200 EX transmission electron microscope. The electron micrographs were taken using the same transmission electron microscope.

For scoring of myelinated axons, the following scale was used: 0 = ultrastructurally normal myelinated axon,

1 = separation in myelin configuration, 2 = interruption in myelin configuration, and 3 = honeycomb appearance in myelin configuration.²⁶ Small, medium, and large myelinated axons were scored separately. From every sample, 100 small, 100 medium, and 100 large myelinated axons were scored. The scoring was performed for 5 samples from each group.

Biochemical Analyses

On the study day, the tissues were homogenized in physiological saline solution and centrifuged at 4000g for 20 minutes. Then, upper clear supernatants were removed for use in the analysis.

Tissue Malondialdehyde Levels

Tissue malondialdehyde (MDA) levels were determined by a method based on a reaction with thiobarbituric acid, as described previously by Ohkawa et al.³⁹ MDA concentrations were expressed as nmol/mg protein.

Tissue Nitric Oxide Levels

Tissue nitric oxide (NO) levels were determined via the method of Miranda et al.³⁴ Results are expressed as nmol/mg protein.

Tissue Tumor Necrosis Factor- α and Interleukin-1 Levels

The tissue tumor necrosis factor- α (TNF α) and interleukin-1 (IL-1) levels were measured using an enzyme-linked immunosorbent assay (ELISA) kit (USCN Life Science, Inc.). The ELISA procedures were performed according to the manufacturer's instructions. Results are expressed as pg/mg.

Tissue Caspase-3 Analysis

The caspase-3 activity was measured using an ELISA kit (USCN Life Science, Inc.). The ELISA procedures were performed according to the manufacturer's instructions. Results are expressed as ng/mg protein.

Tissue Glutathione Peroxidase, Superoxide Dismutase, and Catalase Levels

Total (Cu–Zn and Mn) superoxide dismutase (SOD) (EC 1.15.1.1) activity was determined according to the method described by Sun et al.⁴⁴ The principle of the method is based on the inhibition of nitroblue tetrazolium reduction using a xanthine–xanthine oxidase system as a superoxide generator. SOD activity was expressed as U/mg protein.

The glutathione peroxidase (GSH-Px) activity of the spinal cord was determined by photometric kinetic measurement using a GSH Assay Kit (catalog number 703102, Cayman Chemical) following the oxidation of nicotinamide adenine dinucleotide phosphate spectrophotometrically (Bio-Tek ELx-800) at 340 nm. The GSH-Px concentration was calculated as U/g protein.⁴⁰

Catalase (CAT) activity was measured by a colorimetric method using a Catalase Assay Kit (catalog number 707002, Cayman Chemical) based on the determination of the decrease in the hydrogen peroxide decomposition in a medium by measuring the absorbance changes at 540 nm per minute.²⁵ Activity was expressed as $\mu\text{mol/g}$ protein.

Statistical Analysis

Data analysis was performed using SPSS for Windows, version 11.5 (SPSS, Inc.). To determine if the distributions of continuous variables were normally distributed, we used the Shapiro-Wilk test. The Levene test was used to evaluate the homogeneity of variances. The data are shown as the mean \pm SD or the median (interquartile range [IQR]), where applicable.

Whereas the differences in normally distributed variables among groups were analyzed using 1-way ANOVA, the Kruskal-Wallis test was applied to non-normally distributed data. When the *p* values from 1-way ANOVA or the Kruskal-Wallis test statistics were statistically significant, the post hoc Tukey honest significant difference or Conover's nonparametric multiple comparison test was used to determine which group differed from other groups. A *p* value less than 0.05 was considered statistically significant.

Results

Neurological Outcome

Neurological examination results of the rats in the sham group were all normal, according to the BBB score. Animals in the I/R injury group presented with severe neurological deficits, including complete paraplegia. In the I/R injury group, the median BBB score was decreased significantly compared with the sham group ($p < 0.001$). Postoperatively, the BBB scores of the TQ group were significantly higher than those of the I/R injury group. At 24 hours, the median BBB scores of the I/R injury and TQ groups were 1.5 (IQR 1.00–2.00) and 7.5 (IQR 7.00–8.75), respectively ($p < 0.001$). However, the TQ group exhibited lower median BBB scores than the sham group ($p < 0.001$). No statistically significant differences were found between the TQ and MP groups ($p > 0.05$).

The mean angle recorded in the inclined-plane (IP) test was significantly lower in the I/R injury group than in the sham group ($p < 0.001$). The TQ and MP groups revealed better angles in the IP test compared with the I/R injury group ($p < 0.001$). Nevertheless, the mean angles of the TQ and MP groups were significantly lower than those of the sham group ($p < 0.001$). The BBB and IP scores of the groups are shown in Table 1 and Fig. 1.

Tissue MDA Levels

Tissue MDA levels of the I/R injury group were significantly increased compared with the sham-operated rats ($p < 0.001$). The TQ group exhibited a significantly lower level of tissue MDA compared with the I/R injury group ($p < 0.001$). As with the TQ group, there was a statistically significant difference between the MP and I/R injury groups ($p < 0.001$). No significant difference was observed

in the tissue MDA level between the MP and TQ groups ($p = 0.928$). The levels of MDA in the MP group and the TQ group were significantly increased compared with the sham group ($p < 0.001$ for both).

Tissue NO Levels

The I/R injury group had a significantly elevated level of spinal cord tissue NO compared with the sham group ($p < 0.001$). The TQ group had significantly lower tissue NO levels relative to the I/R injury group ($p = 0.001$). The level of NO in the TQ group was significantly higher than in the sham group ($p < 0.001$). No significant difference was found between the TQ and MP groups ($p = 0.421$).

Tissue SOD, GSH-Px, and CAT Levels

The highest GSH-Px, SOD, and CAT levels were observed in the sham group. Spinal cord I/R injury caused a significant decrease in the amount of GSH-Px, SOD, and CAT, compared with the sham-operated animals ($p < 0.001$). The levels of tissue GSH-Px, SOD, and CAT were significantly higher in the TQ group than in the I/R group ($p = 0.001$, $p < 0.001$, and $p < 0.001$, respectively). MP treatment also caused a statistically significant increase in the levels of tissue GSH-Px, SOD, and CAT compared with the I/R injury group ($p = 0.001$, $p < 0.001$, and $p < 0.001$, respectively). No significant differences were detected in the mean tissue GSH-Px, SOD, and CAT levels between the TQ and MP groups ($p = 0.999$, $p = 0.502$, and $p = 0.654$, respectively).

Tissue Caspase-3 Levels

The I/R injury group showed significant increases in the levels of caspase-3 compared with the sham-operated group ($p < 0.001$). TQ administration after I/R injury attenuated the levels of tissue caspase-3 ($p < 0.001$). The levels were not significantly different between the TQ and MP groups ($p = 1.00$). However, the caspase-3 levels of the TQ and MP groups were significantly higher than in the sham group ($p < 0.001$).

Tissue TNF α Levels

A significantly higher spinal cord TNF α level was observed in the I/R injury group relative to sham-operated animals ($p < 0.001$). TQ administration caused a significant decrease in the level of TNF α , compared with the I/R injury group ($p < 0.001$). Treatment with TQ did not decrease TNF α to the level of the sham group; TNF α levels were significantly different between the TQ and sham groups ($p = 0.027$).

Tissue IL-1 Levels

As expected, the levels of IL-1 were significantly in-

TABLE 1. Neurological examination results relevant to the study groups

Variable	Sham	I/R	MP	TQ	Global <i>p</i> Value, Variance Analysis*
Median BBB score (IQR)	21.0 (21.00–21.00)	1.5 (1.00–2.00)	8.0 (7.00–9.75)	7.5 (7.00–8.75)	<0.001
Mean IP angle ($^{\circ}$), \pm SD	77.2 \pm 4.77	36.7 \pm 5.23	62.2 \pm 6.54	59.7 \pm 6.27	<0.001

* $p < 0.001$ for comparisons between all groups except MP versus TQ.

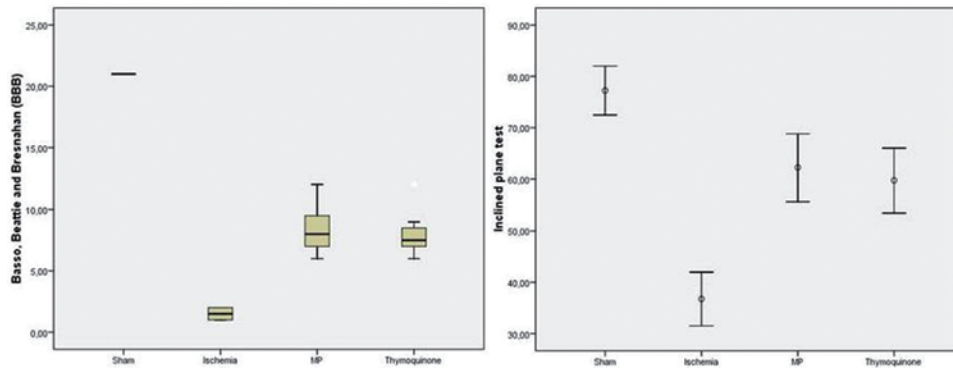


FIG. 1. Box and whisker plots representing the BBB scores and IP test results of the study groups. **Left:** The *horizontal lines* in the middle of each box indicate the median; the top and bottom borders of the boxes mark the 25th and 75th percentiles, respectively. *Whiskers* above and below boxes correspond to the maximum and minimum values. **Right:** The *circle* in the middle of each pair of *whiskers* indicates the arithmetic mean; *whiskers* above and below boxes mark the +1 SD and -1 SD levels, respectively. Figure is available in color online only.

creased in animals that were subjected to I/R injury ($p < 0.001$). The levels of IL-1 were significantly reduced in animals that received TQ treatment ($p < 0.001$), whereas the elevation was significantly higher than in the sham group ($p < 0.001$). There was no statistically significant difference between the TQ and MP groups ($p = 0.788$). The biochemical results of the study are shown in Table 2.

Histopathological Evaluation

In the sham group, light microscopic examination results of the spinal cord samples were normal (Fig. 2A). The I/R injury group exhibited severe neuronal damage, as evidenced by neural pyknosis, intense axonal swelling, loss of cytoplasmic features, and cytoplasmic eosinophilia. In addition, diffuse hemorrhage/congestion and marked necrosis and edema were observed in the gray matter. Polymorphonuclear leukocyte, lymphocyte, and plasma cell infiltration were remarkable in the damaged portion of spinal cord (Fig. 2B). The spinal cord samples of the MP and TQ groups appeared to be protected from the injury, with a greater number of preserved intact motor neurons (Fig. 2C and D).

When the pathological scores were compared, the I/R injury group showed statistically higher scores than the sham group ($p < 0.001$). The pathological scores of the TQ and MP groups were significantly lower than in the I/R group ($p < 0.01$, for both). However, there was no significant difference between the TQ and MP groups ($p = 0.719$). Additionally, the pathological scores of the TQ and MP groups were significantly lower than in the sham group ($p < 0.001$ for both) (Table 3). Agreement on repeated pathological scores calculated by averaging the scores of neuronal degeneration, cellular edema, hemorrhage/congestion, and inflammation ranged from substantial to almost perfect agreement, as shown by coefficient of κ values of 0.728 or higher.

The number of normal motor neurons in the anterior spinal cord of the I/R group was significantly decreased compared with the sham group ($p < 0.001$). The TQ and MP groups' preponderance of normal motor neurons compared with the I/R group was statistically significant ($p < 0.001$ for both). However, the number of normal mo-

tor neurons in the anterior spinal cord of the TQ and MP groups was significantly lower compared with the sham group ($p < 0.001$). The comparison between the TQ and MP groups did not show a statistically significant difference ($p = 0.992$). As a result, both TQ and MP treatment protected the spinal cord from I/R injury histopathologically (Fig. 3 and Table 3).

Ultrastructural Examination

In the transmission electron microscopic examination of the tissue samples of the sham group, ultrastructural pathological changes were not observed in the gray and white matter of the spinal cord. The neurons were ultrastructurally normal in appearance. The intracellular organelles, nuclei, and membranes of the neurons were normal ultrastructurally. The perineuronal tissues did not show any pathological changes (Fig. 4A).

In the transmission electron microscopic examination of the tissue samples of the I/R injury group, severe ultrastructural pathological changes were found in both the white and gray matter. Interruptions and separations in myelin configuration were observed in the small, medium, and large myelinated axons. However, the ultrastructural pathological changes were more severe in the large myelinated axons. In the ultrastructural examination of the gray matter, swollen mitochondria and vacuoles were present inside the cytoplasm of neurons. Additionally, perineuronal edema was present around the neurons in gray matter (Fig. 4B).

In the transmission electron microscopic examination of the tissue samples of the MP group, separations in myelin configuration were observed in the large but in very few of the small and medium myelinated axons. In the ultrastructural examination of the gray matter, swollen mitochondria were present inside the cytoplasm of neurons. The rest of the intracellular organelles, nuclei, and membranes of the neurons were found to be normal ultrastructurally. Additionally, perineuronal edema was present around the neurons in the gray matter (Fig. 4C).

In the TQ group, swollen mitochondria were observed inside the cytoplasm of neurons in the ultrastructural examination of the gray matter. Additionally, perineuronal

TABLE 2. Biochemical results relevant to the study groups

Variable	Sham	I/R	MP	TQ	Global p Value, Variance Analysis
MDA, in nmol/mg protein (IQR)	2.3 (1.57–3.35)*,†,‡	9.9 (8.57–12.90)*,§,¶	5.0 (4.24–7.87)†,§	5.7 (4.50–6.87)†,¶	<0.001
NO, in nmol/mg protein (IQR)	34.5 (29.75–39.86)*,†,‡	84.4 (71.80–110.02)*,§,¶	51.4 (40.54–63.71)†,§	51.8 (42.37–69.39)†,¶	<0.001
SOD, in U/mg protein (IQR)	0.9 (0.75–1.22)*,†,‡	0.3 (0.17–0.34)*,§,¶	0.5 (0.43–0.69)†,§	0.6 (0.49–0.69)†,¶	<0.001
GSH-Px, in U/g protein ± SD	68.2 ± 12.97*,†,‡	27.8 ± 7.28*,§,¶	50.6 ± 9.78†,‡	50.1 ± 9.36†,¶	<0.001
CAT, in μmol/g protein (IQR)	1.4 (0.88–1.91)*,†,‡	0.2 (0.10–0.25)*,§,¶	0.7 (0.58–0.98)†,§	0.7 (0.58–0.95)†,¶	<0.001
Caspase-3, in ng/mg protein ± SD	160.3 ± 45.00*,†,‡	941.8 ± 144.22*,§,¶	482.3 ± 125.60†,§	487.7 ± 116.4†,¶	<0.001
TNFiα, in pg/mg ± SD	20.5 ± 4.51*,†,‡	46.6 ± 8.10*,§,¶	28.5 ± 4.89†,§	28.9 ± 3.99†,¶	<0.001
IL-1, in pg/mg (IQR)	21.7 (16.06–26.10)*,†,‡	83.1 (69.24–94.26)*,§,¶	42.1 (36.35–50.30)†,§	45.3 (35.66–51.20)†,¶	<0.001

* Sham versus I/R (p < 0.001).
 † Sham versus MP (p < 0.05).
 ‡ Sham versus TQ (p < 0.05).
 § I/R versus MP (p < 0.001).
 ¶ I/R versus TQ (p < 0.001).
 ** I/R versus TQ (p < 0.01).
 †† I/R versus MP (p < 0.01).

edema was present. In the ultrastructural examination of the white matter, separations in myelin configuration were found in the medium and large, and in very few of the small, myelinated axons. In addition, interruptions in myelin configuration were present in a very few of the medium myelinated axons. The ultrastructural appearances of the myelinated axons of the TQ group were worse than in the MP group (Fig. 4D).

The I/R injury group showed more disruption in the small, medium, and large myelinated axons compared with the sham group (p < 0.001). When compared with the I/R injury group, MP treatment protected axons of all sizes from ischemic injury (small myelinated axons, p < 0.01; medium myelinated axons, p < 0.01; and large myelinated axons, p < 0.01). Similarly, TQ treatment significantly protected small and large myelinated axons against I/R injury (p < 0.01 for both). However, scores for the medium myelinated axons of the TQ group were not statistically significant compared with the I/R injury group (p > 0.05). Furthermore, MP yielded better results for the small, medium, and large myelinated axons compared with the TQ group (p < 0.01 for all sizes of myelinated axons). The ultrastructural examination results relevant to the study groups are listed in Table 3.

Discussion

To determine whether TQ treatment resulted in reduced secondary damage after I/R injury of spinal cord, we evaluated the biochemical, histological, and ultrastructural alterations at 24 hours after injury. The present study revealed that TQ treatment had a neuroprotective effect, which was not only pronounced in biochemical tests, but also significant in the histological and ultrastructural evaluations, as well as in neurological outcome. The results of TQ treatment were also compared with MP administration.

Steroids have been used in the treatment of acute spinal cord injury since the 1960s.^{11–14} However, because of the considerable risks and side effects of MP, criticisms from later studies have caused a debate about the clinical effect of MP in recovery from spinal cord injury. However, because of its role in inhibition of lipid peroxidation and its antiinflammatory and antiapoptotic effects, MP remains a treatment option until it is supplanted by future evidence-based therapies. That is why we used MP treatment for comparison with TQ treatment.

N. sativa is a flowering plant that has been used for centuries as a natural remedy for a number of diseases. Many active ingredients, such as fixed and essential oils, proteins, alkaloids, and saponin, have been found in the seeds of *N. sativa*.⁴ Alpha-hederin (pentacyclic triterpene saponin) and TQ (2-isopropyl-5-methyl-benzoquinone) are the 2 principal bioactive constituents isolated from the seeds of this flowering plant.¹⁸ Many of the biological activities have been shown to be due to TQ. A number of studies have demonstrated TQ's antioxidant^{28,37} and antiinflammatory effects in the treatment of inflammatory diseases, cancer,⁵¹ atherosclerosis,^{36,41} and diabetes.⁷ Various mechanisms of action have been suggested for TQ, such as inhibition of the cyclooxygenase and 5-lipoxygenase pathways;²²

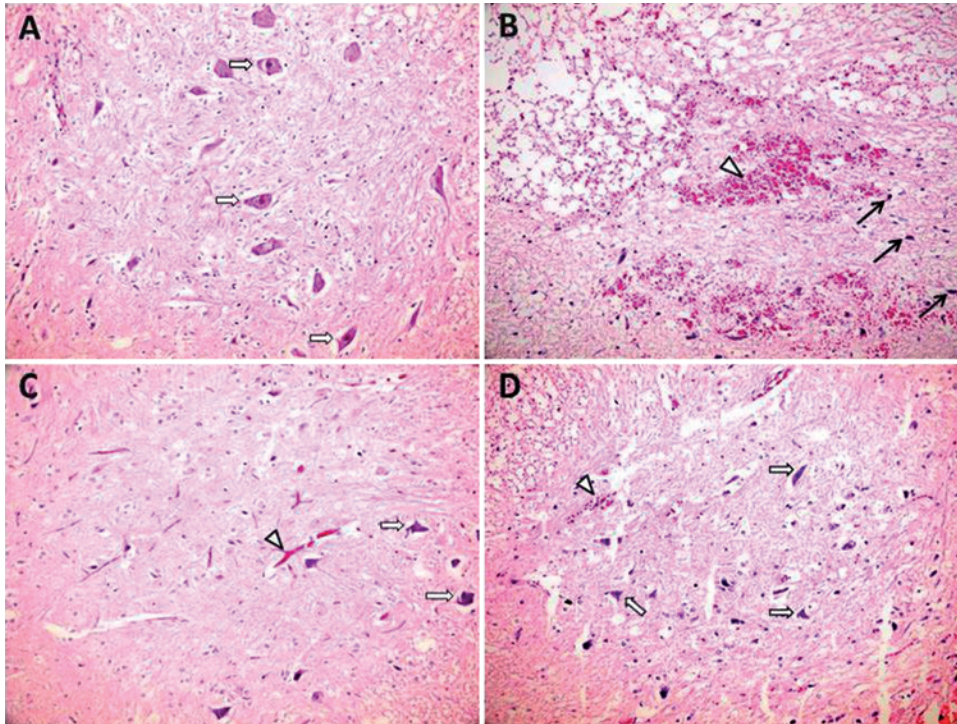


FIG. 2. Representative H & E-stained 5- μ m spinal cord sections from the experimental groups (original magnification $\times 200$). **A:** Sham group showing normal spinal cord parenchyma with normal-appearing neurons (*hollow arrows*). **B:** I/R group showing diffuse hemorrhage and congestion (*hollow arrowhead*), and widespread edema with highly degenerated neurons (*black arrows*) in the gray matter. **C:** MP group showing less hemorrhage and congestion (*hollow arrowhead*), with fewer degenerated neurons and more normal neurons (*hollow arrows*). **D:** TQ group showing more normal neurons (*hollow arrows*) and fewer degenerated neurons with slight hemorrhage and congestion (*hollow arrowhead*). Figure is available in color online only.

suppression of the proinflammatory cytokines IL-1 β and TNF α ,⁸ as well as augmentation of the antioxidant defense through preserving the activity of various antioxidant enzymes, such as CAT, GSH-Px,¹ and SOD.⁴⁹ Other properties ascribed to TQ include its inhibition of nonenzymatic lipid peroxidation in liposomes and its action as a potent free radical and superoxide radical scavenger.^{6,31} TQ is a relatively safe compound, particularly when given orally or intraperitoneally to experimental animals. A dose of 10

mg/kg was administered intraperitoneally to rats in the TQ group, which is below the intraperitoneal LD50 for TQ (57.5 mg/kg) in rats.²

Ischemia-reperfusion injury leaves the spinal cord exposed to oxidative stress, which is accompanied by excess production of free radicals and antioxidant enzyme consumption.⁴⁷ This pathogenic process leads to peroxidation of lipid and protein composition of neuronal tissues, resulting in cytotoxicity, necrosis, and apoptosis. In the present

TABLE 3. Transmission electron microscopy and histopathological results relevant to the study groups

Variable	Sham	I/R	MP	TQ	p Value
Small myelinated axons	0 (0–0)*,†,‡	115 (110–120)*,§,¶	30 (26–32)†,§,**	79 (77–81)‡,¶,**	<0.001
Medium myelinated axons	0 (0–0)*,†,‡	140 (128–144)*,§	91 (87–93)†,§,**	129 (124–132)‡,**	<0.001
Large myelinated axons	4 (2–7)*,†,‡	169 (167–180)*,§,¶	115 (113–119)†,§,**	135 (130–142)‡,¶,**	<0.001
Pathological scores	0 (0–0)††,‡‡,§§	7 (6–9)††,¶¶, ^a	4 (4–5)‡‡,¶¶	4 (4–5)§§, ^a	<0.001
No. of normal neurons \pm SD	47.7 \pm 4.59††,‡‡,§§	20.7 \pm 2.82††,¶¶, ^a	35.5 \pm 3.34‡‡,¶¶	35.0 \pm 3.21§§, ^a	<0.001

* Sham versus I/R ($p < 0.01$).

† Sham versus MP ($p < 0.01$).

‡ Sham versus TQ ($p < 0.01$).

§ I/R versus MP ($p < 0.01$).

¶ I/R versus TQ ($p < 0.01$).

** MP versus TQ ($p < 0.01$).

†† Sham versus I/R ($p < 0.001$).

‡‡ Sham versus MP ($p < 0.001$).

§§ Sham versus TQ ($p < 0.001$).

¶¶ I/R versus MP ($p < 0.001$).

^a I/R versus TQ ($p < 0.001$).

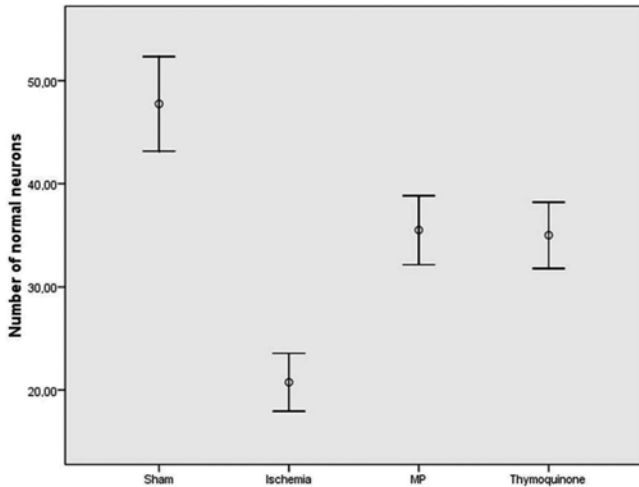


FIG. 3. Whisker plot representing the number of normal neurons in the study groups. The circle in the middle of each pair of whiskers indicates the arithmetic mean; whiskers above and below boxes mark the +1 SD and -1 SD levels, respectively.

study, MDA as a stable product of lipid peroxidation, and NO levels as an indicator of oxidative damage, were analyzed. Both spinal cord tissue MDA and NO levels were significantly increased after I/R injury. TQ and MP treatment decreased the levels of MDA and NO, and the results were statistically significant when compared with the I/R

injury group. In addition, due to elevated oxidative stress in the spinal cord, tissue antioxidant SOD, GSH-Px, and CAT levels were shown to decrease. TQ and MP increased the antioxidant enzyme levels in the ischemic tissue. These findings were thought to be evidence of a marked protection against oxidative stress and significant antioxidant effect of both TQ and MP in rats subjected to I/R injury. Similarly, Al-Majed et al. reported TQ's protective effect in the rat hippocampus against transient forebrain ischemia-induced damage.⁵ The study detected significant decreases in elevated levels of MDA and reversal of the decreased GSH contents, CAT, and SOD activities to normal levels after forebrain ischemia with TQ treatment in rats. The results were consistent with our findings. Furthermore, Mousavi and colleagues investigated the protective effects of *N. sativa* and TQ in cultured PC12 cells as a model of the pathological process of cerebral ischemia.³⁵ They reported that pretreatment with TQ protected the pheochromocytoma cell cultures against ischemic insult through inhibition of intracellular reactive oxygen species generation.

Both necrosis and apoptosis cause neuronal death following ischemic injury of spinal cord. This pathogenic process is associated with increased expression of an interleukin-converting enzyme, caspase-3, which is a reliable marker of apoptotic process activity.²⁰ Apoptotic cells are exposed to autodigestion by caspase-3 as an end product of both the external and internal apoptotic cascades. In the present study, caspase-3 activity was significantly in-

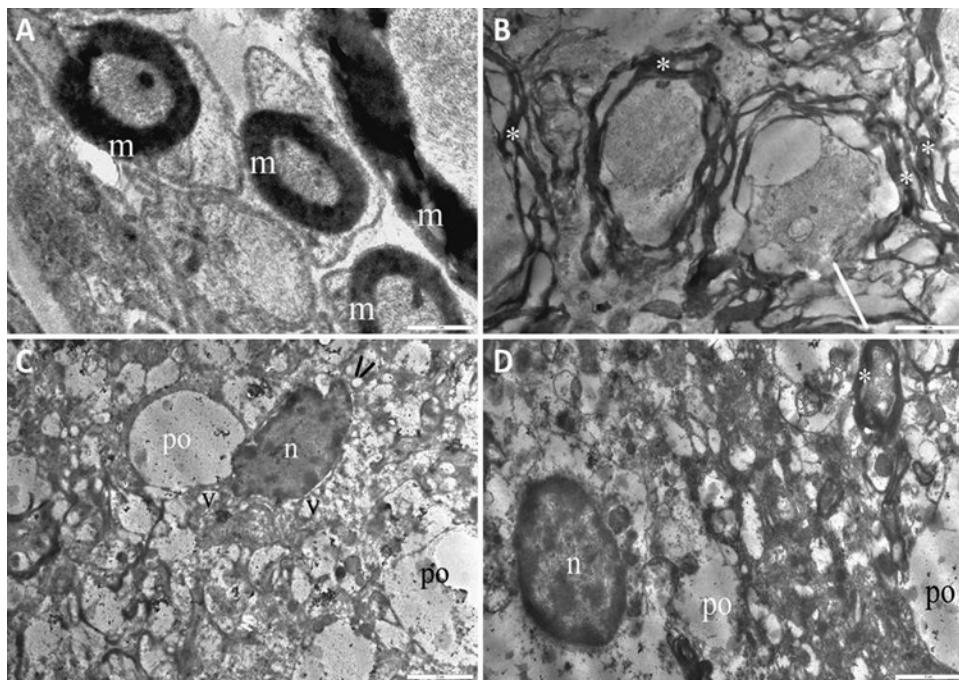


FIG. 4. Transmission electron micrographs of tissue samples. **A:** Micrograph of a tissue sample from the sham group showing normal cord ultrastructure with no pathological changes in the gray and white matter of the spinal cord. **B:** Micrograph of a tissue sample from the I/R injury group showing separations (asterisks) and interruptions (white arrow) in the myelin configuration of myelinated axons. **C:** Micrograph of a tissue sample from the MP group showing perineural edema, swollen mitochondria (black arrows), and vacuoles inside the cytoplasm of neurons. **D:** Micrograph of a tissue sample from the TQ group showing a small amount of perineural edema and separations (asterisk) in the myelin configuration of myelinated axons. Bar = 2 µm; m = ultrastructurally normal myelinated axon; n = nucleus of neuron; po = perineural edema; v = vacuoles.

creased in the ischemic spinal cord samples and the activity of caspase-3 was significantly downregulated in the TQ and MP groups. The results of our study revealed that both TQ and MP treatments significantly inhibited apoptosis in the injured spinal cord segments. These findings are in accordance with Galaly et al.,¹⁷ who reported that apoptotic proteins caspase-3 and Bax expressions were reduced to normal values in gentamicin-induced liver injury with TQ treatment. Similarly, a recent study by Ullah et al.⁴⁸ reported that TQ treatment inhibited the apoptotic cascade by increasing Bcl-2 expression and decreasing the activation of caspase-9 and caspase-3 against ethanol-induced apoptotic neurodegeneration in prenatal rat cortical neurons.

Postischemic inflammation contributes to the early and late stages of reperfusion injury and results in the worsening of neurological outcome. Circulating neutrophil cells and leukocytes are activated to migrate toward the injured area, enter the spinal cord, and contribute to ischemic injury by releasing reactive oxygen products, proteases, and cytokines. Proinflammatory cytokines comprise the early inflammatory component of the secondary injury cascade.²⁴ TNF α and IL-1 are members of the proinflammatory cytokine family and have a pattern of bimodal release in response to ischemic injury.⁴² They are upregulated through the MAPK pathway early in the inflammatory response and trigger the vicious cycle by inducing monocyte recruitment, macrophage–microglial activation, and neutrophil adhesion at the inflammatory site.^{29,38}

We measured levels of the proinflammatory cytokines TNF α and IL-1 to evaluate neuroinflammation after I/R injury. The mean TNF α and IL-1 levels increased in the I/R injury group compared with the control group. Treatment with TQ and MP significantly suppressed the production of TNF α and IL-1, which was probably related to the antiinflammatory activity of TQ and MP. Tekeoglu et al. explored the antiinflammatory effects of TQ on arthritis in a rat model. In their study, they confirmed that TQ treatment was effective in rheumatoid arthritis, with significantly lower clinical and radiological scores, and with, significantly decreased TNF α and IL-1 levels.⁴⁵ Vaillancourt et al. used TQ to treat human fibroblast-like synoviocytes isolated from the synovial membranes of patients with rheumatoid arthritis. They found that TQ dramatically decreased lipopolysaccharide-induced IL-1 β and TNF α production.⁵⁰ Our TNF α and IL-1 measurements are similar to the results given above.

Histopathological examination was performed. Additionally, myelin configuration of the axons in the white matter and ultrastructural changes of the neurons in the gray matter of the spinal cord were evaluated with a transmission electron microscope to obtain more detailed data and compare them with biochemical results. TQ and MP exhibited better histomorphological changes and lower pathological scores with a higher number of normal motor neurons compared with I/R injury. Separations and interruptions in myelin configuration were obvious in all sizes of axons in the I/R injury group when evaluated with a transmission electron microscope. Interruptions were observed in only a few of the medium myelinated axons in the TQ group. However, MP was significantly more effective in preserving the medium myelinated axons.

Both TQ and MP inhibited lipid peroxidation, demonstrated antiinflammatory activity, prevented oxidative stress and apoptosis, and induced the impairment of locomotor activity, according to the BBB scale and IP tests, following I/R injury of the spinal cord. MP treatment was associated with better ultrastructural results than TQ. However, there were no significant differences in terms of pathological scores and number of normal motor neurons in the anterior horn, and there was lack of a significant difference for biochemical parameters between TQ and MP. We assume that this discrepancy may be due to the presence of different pathways affected by TQ.

The results of this study suggest that TQ has beneficial effects for preserving normal spinal cord morphology, ultrastructure, and function by inhibiting apoptosis and reducing inflammation and oxidative stress. However, this study has some limitations. The dose-dependent and delayed biochemical and histopathological assessments can be additionally investigated to attain stronger results for further studies. Furthermore, pretreatment with TQ for 7 days before the I/R injury may not properly imitate I/R injury of the spinal cord under normal circumstances.

Conclusions

This study demonstrated that administration of TQ reduced oxidative stress and inflammation and prevented apoptosis, thereby protecting the spinal cord in rats exposed to I/R injury. Treatment with TQ improves early functional and biochemical results as much as MP; however, MP yields better ultrastructural findings and histomorphological results. TQ may have the potential to be used in the prevention of spinal cord I/R injury. Because this was a pilot study with only 8 animals in each group, functional, biochemical, histological, and ultrastructural analyses in rats using current methods and grading scales may not be sensitive enough to reflect clinically relevant neurological changes. More investigation is needed to explain the exact mechanism underlying the neuroprotective activity of TQ for future clinical development.

References

1. Abdel-Zaher AO, Mostafa MG, Farghly HM, Hamdy MM, Omran GA, Al-Shaibani NK: Inhibition of brain oxidative stress and inducible nitric oxide synthase expression by thymoquinone attenuates the development of morphine tolerance and dependence in mice. *Eur J Pharmacol* **702**:62–70, 2013
2. Al-Ali A, Alkhawajah AA, Randhawa MA, Shaikh NA: Oral and intraperitoneal LD50 of thymoquinone, an active principle of *Nigella sativa*, in mice and rats. *J Ayub Med Coll Abbottabad* **20**:25–27, 2008
3. Al-Ghamdi MS: The anti-inflammatory, analgesic and antipyretic activity of *Nigella sativa*. *J Ethnopharmacol* **76**:45–48, 2001
4. Ali BH, Blunden G: Pharmacological and toxicological properties of *Nigella sativa*. *Phytother Res* **17**:299–305, 2003
5. Al-Majed AA, Al-Omar FA, Nagi MN: Neuroprotective effects of thymoquinone against transient forebrain ischemia in the rat hippocampus. *Eur J Pharmacol* **543**:40–47, 2006
6. Badary OA, Taha RA, Gamal el-Din AM, Abdel-Wahab MH: Thymoquinone is a potent superoxide anion scavenger. *Drug Chem Toxicol* **26**:87–98, 2003
7. Badr G, Mahmoud MH, Farhat K, Waly H, Al-Abdin OZ, Rabah DM: Maternal supplementation of diabetic mice with

- thymoquinone protects their offspring from abnormal obesity and diabetes by modulating their lipid profile and free radical production and restoring lymphocyte proliferation via PI3K/AKT signaling. **Lipids Health Dis** 12:37, 2013
8. Bai T, Yang Y, Wu YL, Jiang S, Lee JJ, Lian LH, et al: Thymoquinone alleviates thioacetamide-induced hepatic fibrosis and inflammation by activating LKB1-AMPK signaling pathway in mice. **Int Immunopharmacol** 19:351–357, 2014
 9. Basso DM, Beattie MS, Bresnahan JC, Anderson DK, Faden AI, Gruner JA, et al: MASCIS evaluation of open field locomotor scores: effects of experience and teamwork on reliability. Multicenter Animal Spinal Cord Injury Study. **J Neurotrauma** 13:343–359, 1996
 10. Bethea JR: Spinal cord injury-induced inflammation: a dual-edged sword. **Prog Brain Res** 128:33–42, 2000
 11. Bracken MB: Steroids for acute spinal cord injury. **Cochrane Database Syst Rev** 1:CD001046, 2012
 12. Bracken MB, Collins WF, Freeman DF, Shepard MJ, Wagner FW, Silten RM, et al: Efficacy of methylprednisolone in acute spinal cord injury. **JAMA** 251:45–52, 1984
 13. Bracken MB, Shepard MJ, Collins WF, Holford TR, Young W, Baskin DS, et al: A randomized, controlled trial of methylprednisolone or naloxone in the treatment of acute spinal-cord injury. Results of the Second National Acute Spinal Cord Injury Study. **N Engl J Med** 322:1405–1411, 1990
 14. Bracken MB, Shepard MJ, Holford TR, Leo-Summers L, Aldrich EF, Fazl M, et al: Administration of methylprednisolone for 24 or 48 hours or tirilazad mesylate for 48 hours in the treatment of acute spinal cord injury. Results of the Third National Acute Spinal Cord Injury Randomized Controlled Trial. National Acute Spinal Cord Injury Study. **JAMA** 277:1597–1604, 1997
 15. Conrad MF, Ye JY, Chung TK, Davison JK, Cambria RP: Spinal cord complications after thoracic aortic surgery: long-term survival and functional status varies with deficit severity. **J Vasc Surg** 48:47–53, 2008
 16. El Mezayen R, El Gazzar M, Nicolls MR, Marecki JC, Dreskin SC, Nomiya H: Effect of thymoquinone on cyclooxygenase expression and prostaglandin production in a mouse model of allergic airway inflammation. **Immunol Lett** 106:72–81, 2006
 17. Galaly SR, Ahmed OM, Mahmoud AM: Thymoquinone and curcumin prevent gentamicin-induced liver injury by attenuating oxidative stress, inflammation and apoptosis. **J Physiol Pharmacol** 65:823–832, 2014
 18. Ghosheh OA, Houdi AA, Crooks PA: High performance liquid chromatographic analysis of the pharmacologically active quinones and related compounds in the oil of the black seed (*Nigella sativa* L.). **J Pharm Biomed Anal** 19:757–762, 1999
 19. Hassan SA, Ahmed WA, Galeb FM, El-Taweel MA, Abu-Bedair FA: In vitro challenge using thymoquinone on hepatocellular carcinoma (HepG2) cell line. **Iran J Pharm Res** 7:283–290, 2008
 20. Hayashi T, Sakurai M, Abe K, Sadahiro M, Tabayashi K, Itoyama Y: Apoptosis of motor neurons with induction of caspases in the spinal cord after ischemia. **Stroke** 29:1007–1013, 1998
 21. Hosseinzadeh H, Parvardeh S, Asl MN, Sadeghnia HR, Ziaee T: Effect of thymoquinone and *Nigella sativa* seeds oil on lipid peroxidation level during global cerebral ischemia-reperfusion injury in rat hippocampus. **Phytomedicine** 14:621–627, 2007
 22. Houghton PJ, Zarka R, de las Heras B, Hoult JR: Fixed oil of *Nigella sativa* and derived thymoquinone inhibit eicosanoid generation in leukocytes and membrane lipid peroxidation. **Planta Med** 61:33–36, 1995
 23. Huang Y, Xie K, Li J, Xu N, Gong G, Wang G, et al: Beneficial effects of hydrogen gas against spinal cord ischemia-reperfusion injury in rabbits. **Brain Res** 1378:125–136, 2011
 24. Isaksson J, Farooque M, Holtz A, Hillered L, Olsson Y: Expression of ICAM-1 and CD11b after experimental spinal cord injury in rats. **J Neurotrauma** 16:165–173, 1999
 25. Johansson LH, Borg LA: A spectrophotometric method for determination of catalase activity in small tissue samples. **Anal Biochem** 174:331–336, 1988
 26. Kaptanoglu E, Palaoglu S, Surucu HS, Hayran M, Beskonakli E: Ultrastructural scoring of graded acute spinal cord injury in the rat. **J Neurosurg** 97 (1 Suppl):49–56, 2002
 27. Khan A, Vaibhav K, Javed H, Khan MM, Tabassum R, Ahmed ME, et al: Attenuation of A β -induced neurotoxicity by thymoquinone via inhibition of mitochondrial dysfunction and oxidative stress. **Mol Cell Biochem** 369:55–65, 2012 (Erratum in **Mol Cell Biochem** 376:197, 2013)
 28. Kruk I, Michalska T, Lichszeld K, Kładna A, Aboul-Enein HY: The effect of thymol and its derivatives on reactions generating reactive oxygen species. **Chemosphere** 41:1059–1064, 2000
 29. Lu K, Cho CL, Liang CL, Chen SD, Liliang PC, Wang SY, et al: Inhibition of the MEK/ERK pathway reduces microglial activation and interleukin-1-beta expression in spinal cord ischemia/reperfusion injury in rats. **J Thorac Cardiovasc Surg** 133:934–941, 2007
 30. Lutterodt H, Luther M, Salvin M, Yin JJ, Perry J, Gao JM, et al: Fatty acid profile, thymoquinone content, oxidative stability, and antioxidative properties of cold-pressed black cumin seed oils. **LWT Food Sci Technol** 43:1409–1413, 2011
 31. Mansour MA, Nagi MN, El-Khatib AS, Al-Bekairi AM: Effects of thymoquinone on antioxidant enzyme activities, lipid peroxidation and DT-diaphorase in different tissues of mice: a possible mechanism of action. **Cell Biochem Funct** 20:143–151, 2002
 32. Marsala M, Yaksh TL: Transient spinal ischemia in the rat: characterization of behavioral and histopathological consequences as a function of the duration of aortic occlusion. **J Cereb Blood Flow Metab** 14:526–535, 1994
 33. Mehri S, Shahi M, Razavi BM, Hassani FV, Hosseinzadeh H: Neuroprotective effect of thymoquinone in acrylamide-induced neurotoxicity in Wistar rats. **Iran J Basic Med Sci** 17:1007–1011, 2014
 34. Miranda KM, Espey MG, Wink DA: A rapid, simple spectrophotometric method for simultaneous detection of nitrate and nitrite. **Nitric Oxide** 5:62–71, 2001
 35. Mousavi SH, Tayarani-Najaran Z, Asghari M, Sadeghnia HR: Protective effect of *Nigella sativa* extract and thymoquinone on serum/glucose deprivation-induced PC12 cells death. **Cell Mol Neurobiol** 30:591–598, 2010
 36. Nader MA, el-Agamy DS, Suddek GM: Protective effects of propolis and thymoquinone on development of atherosclerosis in cholesterol-fed rabbits. **Arch Pharm Res** 33:637–643, 2010
 37. Nagi MN, Mansour MA: Protective effect of thymoquinone against doxorubicin-induced cardiotoxicity in rats: a possible mechanism of protection. **Pharmacol Res** 41:283–289, 2000
 38. Nakamura M, Houghtling RA, MacArthur L, Bayer BM, Bregman BS: Differences in cytokine gene expression profile between acute and secondary injury in adult rat spinal cord. **Exp Neurol** 184:313–325, 2003
 39. Ohkawa H, Ohishi N, Yagi K: Assay for lipid peroxides in animal tissues by thiobarbituric acid reaction. **Anal Biochem** 95:351–358, 1979
 40. Paglia DE, Valentine WN: Studies on the quantitative and qualitative characterization of erythrocyte glutathione peroxidase. **J Lab Clin Med** 70:158–169, 1967
 41. Ragheb A, Elbarbry F, Prasad K, Mohamed A, Ahmed MS, Shoker A: Attenuation of the development of hypercholesterolemic atherosclerosis by thymoquinone. **Int J Angiol** 17:186–192, 2008
 42. Reece TB, Okonkwo DO, Ellman PI, Maxey TS, Tache-Leon

- C, Warren PS, et al: Comparison of systemic and retrograde delivery of adenosine A2A agonist for attenuation of spinal cord injury after thoracic aortic cross-clamping. **Ann Thorac Surg** **81**:902–909, 2006
43. Sedaghat R, Roghani M, Khalili M: Neuroprotective effect of thymoquinone, the nigella sativa bioactive compound, in 6-hydroxydopamine-induced hemi-parkinsonian rat model. **Iran J Pharm Res** **13**:227–234, 2014
 44. Sun Y, Oberley LW, Li Y: A simple method for clinical assay of superoxide dismutase. **Clin Chem** **34**:497–500, 1988
 45. Tekeoglu I, Dogan A, Ediz L, Budancamanak M, Demirel A: Effects of thymoquinone (volatile oil of black cummin) on rheumatoid arthritis in rat models. **Phytother Res** **21**:895–897, 2007
 46. Tiruppur Venkatachallam SK, Pattekhan H, Divakar S, Kadimi US: Chemical composition of *Nigella sativa* L. seed extracts obtained by supercritical carbon dioxide. **J Food Sci Technol** **47**:598–605, 2010
 47. Torres S, Salgado-Ceballos H, Torres JL, Orozco-Suarez S, Díaz-Ruiz A, Martínez A, et al: Early metabolic reactivation versus antioxidant therapy after a traumatic spinal cord injury in adult rats. **Neuropathology** **30**:36–43, 2010
 48. Ullah I, Ullah N, Naseer MI, Lee HY, Kim MO: Neuroprotection with metformin and thymoquinone against ethanol-induced apoptotic neurodegeneration in prenatal rat cortical neurons. **BMC Neurosci** **13**:11, 2012
 49. Umar S, Zargan J, Umar K, Ahmad S, Katiyar CK, Khan HA: Modulation of the oxidative stress and inflammatory cytokine response by thymoquinone in the collagen induced arthritis in Wistar rats. **Chem Biol Interact** **197**:40–46, 2012
 50. Vaillancourt F, Silva P, Shi Q, Fahmi H, Fernandes JC, Benderdour M: Elucidation of molecular mechanisms underlying the protective effects of thymoquinone against rheumatoid arthritis. **J Cell Biochem** **112**:107–117, 2011
 51. Woo CC, Kumar AP, Sethi G, Tan KH: Thymoquinone: potential cure for inflammatory disorders and cancer. **Biochem Pharmacol** **83**:443–451, 2012
 52. Yin F, Guo L, Meng CY, Liu YJ, Lu RF, Li P, et al: Transplantation of mesenchymal stem cells exerts anti-apoptotic effects in adult rats after spinal cord ischemia-reperfusion injury. **Brain Res** **1561**:1–10, 2014

Disclosures

The authors report no conflict of interest concerning the materials or methods used in this study or the findings specified in this paper.

Author Contributions

Conception and design: EC Gökce, R Kahveci. Acquisition of data: EC Gökce, R Kahveci, A Gökce, Aksoy, Sargon, Kısa. Analysis and interpretation of data: A Gökce, Sargon. Drafting the article: EC Gökce. Reviewed submitted version of manuscript: Cemil, Erdogan. Administrative/technical/material support: Güvenç, Alagöz. Study supervision: O Kahveci.

Correspondence

Emre Cemal Gökce, Turgut Özal University, Faculty of Medicine, 06510 Emek, Ankara 06560, Turkey. email: emrecemalgokce@yahoo.com.